Meet the Krash Family

“Get in the van, kids! We’re running late!”

The Krash family of four is headed to Grandpa Krash’s 90th birthday party, and they’re off to a hectic start. Father Jimmy, 43, is at the wheel, impatient because his two kids (JJ, 17 and Ramona, 7) were slow to get ready to leave and now they’re running behind.

On this late November afternoon, they’re traveling down Big River Road - a rural highway - at approximately 65 mph in a minivan, with temperatures dipping down into the 30’s.

“Jimmy, slow down – you’re going too fast for these curvy country roads!”

Jimmy’s wife Jane is nervous because Jimmy is hurrying more than she thinks is safe. Suddenly, just as they reach a blind curve, a deer darts out into the road causing him to jerk the wheel. Tires screeching on the asphalt, the minivan loses control and rolls down a four-foot embankment, flipping over and landing on its top, with the Krash family still inside.

A passing motorist approaches a few minutes later and notices the fresh disturbance in the guardrail. Horrified at the possibility of a recent accident, she stops to investigate and notices the overturned minivan. She yells to the family that she’s getting help and rushes to call 911 for an ambulance, describing the scene as best she can.

Folsom County Fire and EMS crews arrive within nine minutes of dispatch, and identify our four patients who are still inside the vehicle.

A teenage boy appears to be trapped in the third row of the minivan, but the other three patients are removed while crews work to stabilize the vehicle. A helicopter is dispatched to scene.

EMS personnel report they’re smelling gas and, after a careful investigation, identify a gas leak coming from the van.

To everyone’s horror, the van is suddenly engulfed in flames despite efforts from emergency crews, with the teenager still inside.

Crew work quickly to remove JJ from the van. After 23 minutes from the EMS crew’s initial arrival, the patient is extricated.

JJ Krash

JJ is a 17-year-old unrestrained passenger seated in the 3rd row of the family's van. After extrication from the vehicle he is transported to Man in Black Medical Center, a level 3 trauma center, by Folsom County Fire and EMS. Following evaluation of his burns, IV infusion and application of dressings to his burns, it was determined his need for a verified burn center and was transferred to Ring of Fire Burn Center approximately two and half hours later.

Ramona Krash

Ramona is a passenger in the middle row on the driver's side of the family vehicle. She was restrained with lap belt only; Ramona is 7 years old. After being triaged on the scene she was transported to Man in Black Medical Center; a Level 3 trauma center. Further evaluation at the trauma center and an unsuccessful orthopedic procedure determined her need to be at a pediatric facility for her multiple injuries. Ramona was transferred to Rowboat Children's Hospital via Get Rhythm Air Medical Services where she was diagnosed with multiple injuries. Ramona was later was taken to surgery for her orthopedic injuries.

Jimmy Krash

Jimmy is a 43-year-old male who was restrained in a 3-point seatbelt and the driver of the minivan. Jimmy was intubated on the scene and taken via Get Rhythm Air Medical Services to Walk the Line Hospital, a Level 1 trauma center for evaluation of multisystem injuries. Following admission he was taken to surgery for his head injury. A few days post-op he suffered an unplanned event requiring readmission to the ICU. Jimmy was cleared for discharge to a rehabilitation facility.



Jane Krash

Jane is a 38-year-old female who is an unrestrained front seat passenger in the van. Upon EMS arrival she is in full cardiac arrest. EMS providers placed an IO and began CPR. She was transported to Man in Black Medical Center, a Level 3 Trauma Center. Jane had no vital signs on arrival and is in PEA. Multiple procedures were done upon arrival in attempts to resuscitate her. Without success, Jane succumbed to her injuries and died.

Folsom County Fire and EMS
RUN REPORT
Prehospital Patient Care Chart

INCIDENT NUMBER	EMS RESPONSE NUMBER	CALL SIGN	VEHICLE #	INCIDENT DATE
33-4556				11/17/2017

INCIDENT ADDRESS	INCIDENT CITY	INCIDENT STATE	INCIDENT ZIP CODE
Big River Road	Jackson	Ohio	51503

INCIDENT COUNTY	INCIDENT LOCATION TYPE:
Folsom	Street

COMPLAINT REPORTED BY DISPATCH: MVC rollover	PRIMARY PAYMENT

INCIDENT/PATIENT DISPOSITION
- ☒ Treated, Transport EMS
- ☐ No Patient Found
- ☐ Treated, Transferred care
- ☐ Cancelled
- ☐ No Treatment Required
- ☐ Pt Refused Care
- ☐ Treated & Released
- ☐ Dead at Scene
- ☐ Treated, Transported Private Vehicle
- ☐ Treated, Transported Law Enforcement

EMERGENCY MEDICAL DISPATCH PERFORMED
- ☐ No
- ☒ Yes w/pre-arrival instructions
- ☐ Yes w/out pre-arrival instructions
- ☐ Yes Unk if pre-arrival instructions given

LEVEL OF CARE - UNIT
- ☐ BLS, EMR
- ☐ BLS, EMT
- ☐ BLS, AEMT
- ☐ ALS, AEMT
- ☒ ALS, Paramedic
- ☐ ALS, Nurse
- ☐ ALS, Physician
- ☐ Specialty Critical Care

TYPE OF SERVICE REQUESTED
- ☒ 911 Response
- ☐ ED to ED Transfer
- ☐ Intercept
- ☐ Mutual Aid

PRIMARY ROLE OF THE UNIT
- ☒ Transport
- ☐ Non-transport
- ☐ Supervisor
- ☐ Rescue

LEVEL OF SERVICE
- ☐ BLS, Emergency
- ☒ ALS, Level 1 Emergency
- ☐ ALS, Level 2
- ☐ Specialty Care Transport
- ☐ Helicopter
- ☐ Not Applicable

 # OF PATIENTS ON SCENE
- ☐ Single
- ☐ None
- ☒ Multiple

MASS CASUALTY
- ☐ Yes
- ☒ No

PATIENT LAST NAME	PATIENT FIRST NAME	MI
Krash	JJ	

PATIENT ADDRESS ☐ SAME AS INCIDENT	PATIENT CITY	PATIENT STATE	PATIENT ZIP CODE

AGE	DATE OF BIRTH	GENDER	RACE
17	8/9/2000	☐ Female ☒ Male	Black

CURRENT MEDICATIONS	ALLERGIES	PERTINENT HISTORY
None	None	UNK

INJURY PRESENT
- ☒ Yes
- ☐ No

CAUSE OF INJURY MVC

TYPE OF INJURY
- ☒ Blunt
- ☐ Penetrating
- ☒ Burn
- ☐ Not Known

ALCOHOL/DRUG USE INDICATORS
- ☒ None
- ☐ Pt admits to drug use
- ☐ Smell of alcohol on breath
- ☐ Pt admits to alcohol use
- ☐ Alcohol and/or drug paraphernalia at scene

CHIEF COMPLAINT	CONDITION CODE
Burn s/p MVC	

CHIEF COMPLAINT ANATOMIC LOCATION
- ☐ Abdomen
- ☒ Extremity Lower
- ☐ General/Global
- ☐ Chest
- ☐ Back
- ☐ Extremity Upper
- ☐ Head
- ☐ Neck
- ☐ Genitalia

CHIEF COMPLAINT ORGAN SYSTEM
- ☐ CNS/Neuro
- ☐ OB/GYN
- ☐ Pulmonary
- ☐ Global
- ☐ Renal
- ☐ Cardiovascular
- ☐ Psych
- ☒ Skin
- ☐ Musculoskeletal

CARDIAC ARREST
- ☐ Yes, Prior to Arrival
- ☐ Yes, After Arrival
- ☒ No

RESUSCITATION
- ☐ Defibrillation
- ☐ None-DOA
- ☐ Ventilation
- ☐ None-DNR
- ☐ Chest Compressions
- ☐ None-Signs of life

CAUSE OF CARDIAC ARREST
- ☐ Presumed Cardiac
- ☐ Respiratory
- ☐ Unknown
- ☐ Trauma
- ☐ Electrocution
- ☐ Drowning
- ☐ Other

USE OF SAFETY EQUIPMENT
- ☐ N/A
- ☐ Lap Belt
- ☐ Shoulder Belt
- ☐ Protective Clothing
- ☒ Not Known
- ☐ Helmet Worn
- ☐ Protective Non-Clothing Gear
- ☐ Other
- ☐ Child Restraint
- ☐ Eye Protection
- ☐ Personal Floatation Device

AIRBAG DEPLOYMENT
- ☐ None Present
- ☒ Deployed Front
- ☐ Not Deployed
- ☐ Deployed Side
- ☐ Deployed Other

BARRIERS TO EFFECTIVE CARE
- ☐ Development Impaired
- ☐ Physically Impaired
- ☐ Unattended/Unsupervised
- ☐ Hearing Impaired
- ☐ None
- ☐ Physical Restraint
- ☐ Unconscious
- ☐ Language
- ☐ Speech Impaired

RESPONSE MODE	TRANSPORT MODE
☐ ← Lights/Sirens →	☒
☐ ← No Lights/No Sirens →	☐
☐ ← Initial Lights/Sirens Downgraded to no Lights/Sirens →	☐
☐ ← Initial No Lights/Sirens Upgraded to Lights/Sirens →	☐

Initial Call for Help	15:34	Unit Left Scene	16:11
Unit Notified	15:34	Patient arrived at Destination	16:24
Unit En Route	15:36	Transfer of Patient Care	:
Arrive on Scene	15:43	Incident Completed	:
Arrived at Patient	15:43		

PRIOR AID

PERFORMED BY	MEDICATIONS/ PROCEDURES	OUTCOME

INCIDENT NUMBER	UNIT ID	INCIDENT DATE
33-4556		11/17/2017

TRAUMA TRIAGE CRITERIA

- ☐ 2nd/3rd burn >10% BSA or face/feet/hand/genital/airway
- ☐ Amp prox to wrist/ankle
- ☐ Decreasing LOC
- ☐ GCS Motor >4
- ☐ GCS Total ≥13
- ☐ Head/neck/torso crush
- ☐ Extremity inj w/neurovasc comp
- ☐ Extremity crush
- ☐ Torso inj w/pelvic fx
- ☐ Flail chest
- ☐ Torso inj w/abd tender/ distended/seatbelt sign
- ☐ LOC ≥5 min
- ☒ Mech of inj
- ☐ Did not meet any triage criteria
- ☐ Pen inj head/neck/torso
- ☐ Pen inj prox to knee/elbow w/neurovasc comp
- ☐ Spinal cord inj
- ☐ Special Considerations
- ☐ 2+ prox humerus/femur fxs

ADULTS ONLY

- ☐ Pulse >120 w/hemor shock
- ☐ Tension pneumothorax
- ☐ Resp <10 or >29
- ☐ Required intubation
- ☐ SysBP <90, or no radial pulse w/carotid pulse

PEDS ONLY

- ☐ Poor perfusion
- ☐ Resp distress/failure

SYMPTOMS PRIMARY=P ASSOCIATED=A

P	A	
☐	☐	None
☐	☐	Bleeding
☐	☐	Breathing
☐	☐	Changes in Responsiveness
☐	☐	Choking
☐	☐	Death
☐	☐	Device/Equip Prob
☐	☐	Diarrhea
☐	☐	Drainage/Discharge
☐	☐	Fever
☐	☐	Malaise
☐	☐	Mass/Lesion
☐	☐	Mental/Psych
☐	☐	Nausea/Vomiting
☐	☒	Pain
☐	☐	Palpitations
☐	☐	Rash/Itching
☐	☐	Swelling
☐	☐	Transport Only
☐	☐	Weakness
☒	☐	Wound

PROVIDER IMPRESSION PRIMARY=P SECONDARY=S

P	S	
☐	☐	Abd pain
☐	☐	Airway obstruct
☐	☐	Allergic rxn
☐	☐	Altered LOC
☐	☐	Behavior/psych
☐	☐	Cardiac arrest
☐	☐	Cardiac arrhythmia
☐	☐	Chest pain
☐	☐	Diabetic
☐	☐	Electrocution
☐	☐	Hyperthermia
☐	☐	Hypothermia
☐	☐	Hypovolemia/shock
☐	☐	Inhalation/toxic gas
☐	☐	Inhalation/smoke
☐	☐	Death
☐	☐	Poisoning/drug OD
☐	☐	OB/delivery
☐	☐	Resp arrest
☐	☐	Resp distress
☐	☐	Seizure
☐	☐	Sexual assault/rape
☐	☐	Stings/bites
☐	☐	Stroke/CVA
☐	☐	Syncope
☒	☐	Injury
☐	☐	Vag bleed

MEDICATIONS

TIME	MEDICATION	DOSE	ROUTE	REACTIONS See Ref. Sheet
:				
:				
:				
:				
:				

PROCEDURES

TIME	PROCEDURE	# ATTEMPTS	SUCCESSFUL	COMPLICATIONS See Ref. Sheet
15:52	IV L AC; LR	1	☒ YES ☐ NO	
:			☐ YES ☐ NO	
:			☐ YES ☐ NO	
:			☐ YES ☐ NO	
:			☐ YES ☐ NO	

VITAL SIGNS See Ref. Sheet

TIME	PULSE	SYS BP	DIA BP	RESP	O2 SAT	GCS EYE	GCS VERBAL	GCS MOTOR
15:51	100	112	77	24	95	4	5	6
:								
:								
:								
:								

ADV DIRECTIVE

- ☐ State DNR Form
- ☐ Other Healthcare DNR
- ☐ Family Request DNR (no form)
- ☒ None
- ☐ Living Will
- ☐ Other

DESTINATION

Man in Black Medical Center

TYPE OF DESTINATION

- ☒ Hosp ED/OR/L&D
- ☐ Other EMS (air)
- ☐ Other EMS (ground)
- ☐ Other

REASON FOR CHOOSING DESTINATION

- ☒ Closest
- ☐ Diversion
- ☐ Family Choice
- ☐ Insurance
- ☐ Law Enforcement Choice
- ☐ On-line Med Control
- ☐ Other
- ☐ Pt. Choice
- ☐ Pt. Physician's Choice
- ☐ Protocol
- ☐ Specialty Resource Center

ED DISPOSITION

- ☐ Admit-floor
- ☐ Admit-ICU
- ☐ Death
- ☐ Discharge
- ☒ Transfer-other hosp

HOSPITAL DISPOSITION

- ☐ Death
- ☐ Discharge
- ☐ Transfer-other hosp
- ☐ Transfer-nursing home
- ☐ Transfer-other
- ☐ Transfer-rehab

NARRATIVE:

3rd row passenger of van went off road down a ditch. Upon EMS arrival patient was trapped in vehicle. During patient extrication the smell of gas was noticed and the vehicle caught fire just as patient was extricated. 23 minutes after arrival patient loaded into ambulance. An IO was placed in the the right tibia and fluids began.

CREW MEMBER	CREW MEMBER	CREW MEMBER
CREW MEMBER	CREW MEMBER	CREW MEMBER

HISTORY & PHYSICAL

Patient Name: Krash, JJ
Date: 11/17/2017

Mechanism of Injury: MVC back passenger in 3rd row of van, unknown restraint, burns from vehicle igniting.

Injuries: 8% TBSA, full thickness with blistering burns to RLE, circumferential, 1st degree burn to RUE, rt hand, hypothermia 34.9 C

Other Medical Problems: none

Incidental Findings: None

Admission Plan of Care: transfer out to burn center

Chief Complaint(CC): Multiple Trauma with 8% TBSA burns

History of Present Illness (HPI): 17yom, unrestrained 3rd row backseat passenger of van involved in MVC with loss of control and down an embankment, landing on its top, reported patient's vehicle engulfed in flames. Pt was trapped for approximately 23 minutes, extricated just as vehicle catches on fire. Transport via ambulance, 'Folsom County Fire and EMS'

Past Medical History (PMH): none

Past Surgical History: none

Social history:

- **Smoking status:** **No**
- **Smokeless tobacco:** **No**
- **Alcohol use:** **No**

Social History Main Topics

• Smoking status:	Never Smoker
• Smokeless tobacco:	Never Used
• Alcohol use	No
• Drug use:	No
• Sexual activity:	Not on file

Family history: Not on file

Medications: None

Allergies:
Allergies not on file

REVIEW OF SYSTEMS [List positives and pertinent negatives]**:**
Constitutional Symptoms:

Eyes:
Ears, Nose, Mouth, Throat: Clear, non carbonaious color or sputum
Cardiovascular: S, S2 normal monitor ST
Respiratory: Chest symmetrical, lungs clear
Gastrointestinal: Active bowel sounds, soft nontender
Genitourinary: Normal
Musculoskeletal: MAE strongly and equal, full ROJM
Skin/Breast: 8% full thickness burn with blistering to RLE, partial thickness burn RUE right hand
Neurological: GCS 15, PERLA @ 3mm
Psychiatric: noncontributory
Endocrine: noncontributory
Hematologic/Lymphatic: noncontributory
Allergic/Immunologic: NKA

PHYSICAL EXAM:
Initial Vital Signs
BP 115/65 mmHg | **Pulse** 85 | **RR** 18 | **Temp:**34.9 | **Ht** not on file | **Wt** 18.6 kg (x lb) | **SpO2** 100%

PRIMARY SURVEY
AIRWAY: Patent, trachea midline. Phonation is normal.
BREATHING: Symmetric chest rise and fall. Breath sounds present bilaterally.
CIRCULATION: No active signs of bleeding, strong distal and central pulses. Skin cool, dry and pale
DISABILITY: Moves extremities normally x 4. No lateralizing neurologic signs. Pupils 3 mm equal and reactive bilaterally.
Glascow Coma Scale:
EYES = 4
VERBAL = 5
MOTOR= 6
GCS = 15

SECONDARY SURVEY
GENERAL: AOx3, in no acute distress
HEAD/FACE, EYES, ENT: Head atraumatic, ENT exam normal, conjunctivae/corneas clear. PERRL, EOM's intact. No battle signs or raccoon eyes present
NECK: Supple without obvious injury
CHEST/RESPIRATORY: Resp: No chest wall deformities or tenderness, resp effort normal. No wheezing, rhonchi or rales
CVS: RRR, no murmurs, gallops or rubs
ABDOMEN/GI: exam normal
PELVIS: stable with no gross deformities, without obvious tenderness to palpation
GU and RECTAL: no gross hematuria, no trauma or blood indicated
BACK / TLS SPINE: No obvious tenderness or bony step off deformities
EXTREMITIES/MSK: Burns to rt hand, 1st degree
SKIN: TBSA 8%, 3rd degree burns to RLE, circumferential
NEURO: No motor or sensory abnormalities
PSYCH:

Laboratory Results: Trauma panel within normal limits
Labs:

Imaging (if any) During ED Visit:

Medications Ordered/Given During ED Visit:

Diagnosis: 8% TBSA, 3rd degree burns to RLE, circumferential, 1st degree burn to RUE, rt hand, hypothermia 34.9 degrees

Medical Decision Making: transfer out to burn center

Disposition: transfer out to Ring of Fire Burn Center

Emergency Services Trauma Flow Sheet

Example

Man In Black Medical Center

JJ Krash 17yo male
Birthdate: 08/09/2000
MRN 101010101

Date: 11/17/2017 Patient Arrival Time: 16:24

N/A Pre-Hospital Treatment		
Transporting Ambulance **Folsom County EMS**		
O2 @ 2_L/min/	IV: Needle size_#18 L AC	**X_Backboard**
NC NRB Ambu	LR	Long___ Short___ Ked___
Airway	Medications	Scoop
Oral Nasal Other	_____	Bilateral Head Supports
ET tube # _____ @ cm	C-Collar on: Yes_X ___No	Splint on
	_____	Ice on
CPR started @ (time)	_____	Dressing
		Other

Date of Injury: 11/17/2017 Time of Injury: unk Pre-hospital trauma team alert notification: X Yes No

Hospital Trauma Team Activation Yes X No____ Time of Trauma Team Activation: 16:13

Trauma Team Members		
Team members notified:	Time Called	Time Arrived
‰ Nurses x	1613	1620
‰ Physician / CNP / PA	1613	1628
‰ Lab	1613	
‰ X-ray	1613	1619
‰ Other		

Type of Vehicle	
X **Car**	Pedestrian
Truck	ATV
Motorcycle	Boat
Bicycle	
Other _____	

Mechanism of Injury		
Speed of vehicle	65 MPH	**Rollover**
Number of vehicles _____		Ejected
1 2 3 >3		Rearend
Steering wheel deformity		T-Bone
Starred windshield		Head on

Restraint Devices	
Lap belt	**Airbag deployed**
Shoulder belt	Helmet
Car seat	**Unrestrained**

Fall	Penetrating	Blunt	Thermal	Other
‰ Fell from: _____	‰ GSW _____	‰ Assault _____	**Burn** _____	‰ Hanging _____
	‰ Stabbing _____	‰ Crush _____	‰ Heat exposure	‰ Near drowning
Height_____ ft.	‰ Other _____	‰ Other _____		
			‰ Cold exposure	‰ Animal related

Emergency Services Trauma Flow Sheet

Example

Initial Assessment

AIRWAY

X Patent	Suctioning
Oral Airway	Bag Mask
Nasal Airway	O2 2 L.
ET _____	Comments
Trach	
Crico	

BREATHING

Spontaneous R	Spontaneous L		Respiratory Effort	
			X Normal	Agonal
X	X	Lung sounds	Shallow	Nasal flaring
		Clear	Stridor	Tachypnea
		Rales	Dyspnea	Grunting
		Rhonchi/Wheezes	Retracting	Absent
		Decreased	Intercostal	Paradoxical
		Absent	Substernal	Cough

Smoker Yes X No Unk

CIRCULATION

Capillary Refill:	None	Delayed (> 2 sec)	X Normal (< 2 sec)	
Pulses Present:	Carotid	Femoral	**Radial**	Pedal
Palpated Pulse	**X Regular**		Irregular	
Heart tones	**X Audible**		Absent	
Jugular Vein Distension	**X No**	Yes		
Bleeding	Controlled	Uncontrolled	**X NA**	
Skin Color	Pink		Dusky	
	X Pallor		Cyanotic	
	Flushed		Mottled	

DISABILITY

Glasgow Coma Score		Initial	Disch
Eye Opening		4	4
Spontaneously	4		
To Speech (Shout)	3		
To Pain	2		
No Response	1		
Verbal Response		5	5
Oriented (Coos, Babbles)	5		
Confused (Consolable, Cry)	4		
Inappropriate Words (Persistent Cries, Screams)	3		
Incomprehensible Words (Grunts, Restless)	2		
No Responses	1		
Motor		6	6
Obeys (Spontaneous)	6		
Localized Pain	5		
Withdrawal to Pain	4		
Flexion to Pain (Decorticate)	3		
Extension to Pain	2		
No Response to Pain	1		
Total GCS Score		**15**	**15**

Allergies: none

Tetanus: _ | LMP: NA | Wt: unk

Procedures

Time	Procedure	Results
	ET Tube _____	Size _____ Secured @ _____ cm FiO2 _____ %
PTA	Central Line/ IV PIV LAC	Size 18 Fr Site LAC Solution_
16:27	Warming Measures	**X Fluids** Mechanical **X Bair Hugger** **X Blankets**
	NG Tube	Size _____ Color _____
	Foley / Quick Cath	Size _____ Color
	Neck immobilization C-Collar Applied: PTA	CMS: Before _____ After _____
	Splinting _____	Location: _____

Area of Injury

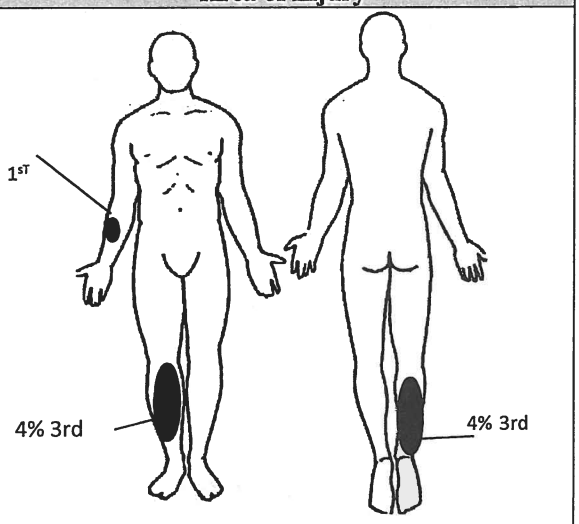

A = Abrasion	Fc = Closed Fracture	OW = Open Wound
B = Burns	Fd = Dislocation	P = Paralysis
C = Crepitus	Fo = Open Fracture	S = Edema
D = Deformity	L = Laceration	Ta = Total Amputation
E = Ecchymosis		Na = Near Amputation

Emergency Services Trauma Flow Sheet

Example

Secondary Assessment

Head/Scalp		Eyes	Mouth	Ears	
X Intact	Rash	X PEARL	X Intact	X No drainage	
Laceration	Burns	Raccoon eyes	Teeth	Drainage	
Abrasions	Pain	EOMS follows	Missing teeth	Right	Left
Bruising	Battle Signs	Visual Acuity OD ___/___	Dentures intact	Clear	Clear
		OS ___/___	Comments_____	Blood	Clear

Neck		Chest		Heart Sounds
Intact	X C-Collar	X Symmetrical	Chest Pain	X Present
Swelling	Pain	Asymmetrical	Location _____	Distant
Trachea midline		Paradoxical movement	Time of onset _____	Absent
Trachea deviated		Location _____	Activity @ onset _____	
Sub-q emphysema		Crepitus	Flail chest	
Difficulty swallowing		Location_____	ther _____	

Abdomen / Pelvis / GU

Abdomen			Bowel Sounds	Pelvis
X Soft	Distended	Last Intake:	X Present	X Intact
X Nontender	Rigid	Food breakfast _____	Absent	Pain _____
Tender		Liquid _____	Hyperactive	Blood at meatus _____
Comments: _____			Hypoactive	Blood at rectum _____
				Instability _____

Posterior	Extremities
X Intact	Intact
Deformity	Fracture
Pain	X Pain
Comments _____	Deformity
	X Comments 12% TBSA RLE, 3rd° circumferential, 1st° RUE

Time	Temp	P	R	BP	SaO2	O2 L/min	Pupil Reaction (S-slow, U-unequal, B-brisk, D-dilated, F-fixed, = - Equal, C-closed by swelling)		Pain Scale 0-10 Pain Scale	Pain Type	Comments
16:25	34.9	85	18	115/P	100	2L	Right	Left	7		Warm blankets and bair hugger
				/							
1730	36.4	88	20		100	2L			6		
				/							
1830	37.0	82	16	1	100	2L			5		
				/							
				/							
				/							
				/							
				/							
				/							
				/							

Medications Given

Medication	Dose	Route	Time Given	Initials
Fentanyl	50mcg	IV	1645	BTS
Zofran	4mg	IV	1642	BTS
Fentanyl	50mg	IV	1815	BTS
TDAP	0.5mg	IM	1800	BTS

Emergency Services Trauma Flow Sheet

Example

Input				Output			
Source	**Prior to Arrival**	**ED**	**Total**	**Source**	**Prior to Arrival**	**ED**	**Total**
LR			1.5L	Urine		200	
				Emesis			
				Chest Tube			
				Other			
Blood							
Fresh Frozen Plasma							

Personal Belongings
Clothes
Purse
Wallet
Jewelry
Given to:
Name
Relationship
Nursing Staff

Nurse Notes: 17 yo male, unrestrained, 3rd row passenger in vehicle, arrived at 1624 with burns to RUE and RLE following a rollover MVC that caught fire as patient was being extricated. IV placed by EMS prior to arrival. Full thickness wounds on right leg, circumferentially and 1st degree burn on right forearm. 12% TBSA. Patient hypothermic upon arrival. Dr Benny requested transferred to burn center for treatment of wounds. Burned area covered with dressing. 1844 patient transferred to Ring of Fire Medical Center by I've been Everywhere Ambulance.

RN Signature: BTS

Q/trauma2/trauma/trsystemdevelopment/sdtaskford/flowsheetdraft/09-09

HISTORY & PHYSICAL

Man in Black Medical Center

Level III Trauma Center

Patient Name: Krash, Ramona
Date: 11/17/2017

Mechanism of Injury: MVC backseat passenger, lapbelt restraint only

Injuries: GR3 Spleen Lac, L tib/fib fxs, Mult Abras, Mult Contusions, and RFA lac

Other Medical Problems: asthma, ADHD

Incidental Findings: None

Admission Plan of Care: OR for reduction of tib/fib fx, nonoperative treatment for GR3 Splenic Lac

---

Chief Complaint(CC): Multiple Trauma

History of Present Illness (HPI): 7yof, lap belt only restrained middle backseat passenger of van involved in MVC with loss of control and down an embankment, landing on its top, reported patient's vehicle engulfed in flames. Patient without burn injuries. Transport via Folsom County Fire and EMS

Past Medical History (PMH): none

Past Surgical History: none

Social history:

- **Smoking status:** **No**
- **Smokeless tobacco:** **No**
- **Alcohol use:** **No**

Social History Main Topics

• Smoking status:	Never Smoker
• Smokeless tobacco:	Never Used
• Alcohol use	No
• Drug use:	No
• Sexual activity:	Not on file

Family history: Not on file

Medications: Albuterol inhaler for asthma, Adderall

Allergies:
Allergies not on file

REVIEW OF SYSTEMS [List positives and pertinent negatives]**:**

Constitutional Symptoms:
Eyes: NEGATIVE
Ears, Nose, Mouth, Throat: ENT EXAM NORMAL
Cardiovascular: S1 AND S2 NORMAL
Respiratory: NORMAL BREATH SOUNDS, NO RESPIRATORY DISTRESS, NO WHEEZING
Gastrointestinal: Abdomen soft with guarding, tenderness with concern for organ injury
Genitourinary:
Musculoskeletal: LLE obvious deformity, RUE obvious deformity, distal pulses are palpable in lt foot and RUE, Neuro intact at distal Lt Lower Extremity, otherwise moving extremities appropriately. RUE FA 3cm lac.

Skin/Breast: Normal coloration and turgor, no rashes, no suspicious skin lesions noted. RUE FA lac

Neurological: No motor or sensory abnormalities
Psychiatric: Affect normal, Mood normal , Judgment normal.
Endocrine:
Hematologic/Lymphatic:
Allergic/Immunologic: NONE

PHYSICAL EXAM:
Initial Vital Signs
BP 113/60 mmHg | **Pulse** 85 | **RR** 20 | **Temp:**98.4| **Ht** not on file | **Wt** 18.6 kg (x lb) | **SpO2** 100%

PRIMARY SURVEY
AIRWAY: Patent, trachea midline. Phonation is normal.
BREATHING: Symmetric chest rise and fall. Breath sounds present bilaterally.
CIRCULATION: Pulses 2+ throughout.
DISABILITY: Moves extremities normally x 4. No lateralizing neurologic signs. Pupils 3 mm equal and reactive bilaterally.
Glascow Coma Scale:
EYES = 4
VERBAL = 5
MOTOR= 6
GCS = 15

SECONDARY SURVEY
GENERAL: AOx3, in no acute distress
HEAD/FACE, EYES, ENT: Head atraumatic, ENT exam normal, conjunctivae/corneas clear. PERRL, EOM's intact. No battle signs or raccoon eyes present
NECK: Supple without obvious injury
CHEST/RESPIRATORY: Resp: No chest wall deformities or tenderness, resp effort normal. No wheezing, rhonchi or rales
CVS: RRR, no murmurs, gallops or rubs
ABDOMEN/GI: Abdomen soft with guarding, tenderness with concern for organ injury, CT Abdomen confirms GR3 Spleen Lac
PELVIS: stable with no gross deformities, without obvious tenderness to palpation
GU and RECTAL: no gross hematuria, no trauma or blood indicated
BACK / TLS SPINE: No obvious tenderness or bony step off deformities
EXTREMITIES/MSK: LLE obvious deformity, RUE obvious deformity, distal pulses are palpable in lt foot and RUE, Neuro intact at distal Lt Lower Extremity, otherwise moving extremities appropriately. RUE FA 3cm lac. Imaging confirms Lt Tib/Fib Fxs
SKIN: Normal coloration and turgor, no rashes, no suspicious skin lesions noted. RUE FA lac
NEURO: No motor or sensory abnormalities
PSYCH: Affect normal, Mood normal , Judgment normal.

Imaging (if any) During ED Visit:

Study Results:

CT-TRAUMA ABD/PEL W CON

Study Result

PROCEDURE: CT-TRAUMA ABD/PEL W CON

DATE OF EXAM: 11/17/2017
DEMOGRAPHICS: 7 years old Female

INDICATION: Trauma, Abdominal Injury
Contrast utilized and the relevant clinical information: History: Trauma

COMPARISON: No existing relevant imaging study corresponding to the same anatomical region is available.

TECHNIQUE: Contiguous axial slices of the abdomen and pelvis were submitted after the IV administration of contrast. No oral contrast was utilized. Additional coronal reformatted images were submitted.

DOSE OPTIMIZATION: CT radiation dose optimization techniques (automated exposure control, and use of iterative reconstruction techniques, or adjustment of the mA and/or kV according to patient size) were used to limit patient radiation dose.

FINDINGS:
CT ABDOMEN:

Inferior chest: The lung bases are clear. The heart size is normal. There is no pericardial or pleural effusion.

Gallbladder: The gallbladder is distended with a smooth thin wall.

Biliary tree: There is no evidence for intra-or extrahepatic biliary ductal dilatation.

Liver: The liver demonstrates normal appearance. No focal abnormalities are seen. Normal contrast enhancement is noted.

Spleen: Grade 3 Spleen Lac.

Pancreas: Normal morphology without masses or inflammatory changes.

Adrenals: Normal size without masses.

Kidneys: Normal size and morphology. No masses or hydronephrosis. No stones are identified. Delayed images show excretion of contrast into non-dilated renal collecting systems.

Vasculature: No evidence of aneurysm or other significant vascular pathology. No evidence of dissection.

Lymphatic system: No pathologically enlarged lymph nodes are seen.

Bowel: The stomach is normally distended with no focal wall abnormality. The duodenum is normal in caliber along its course. No focal abnormality is seen. The small bowel is normal caliber. There is no focal stricture or dilatation. The colon is normal in caliber. No focal abnormality is seen. The appendix is seen and is normal.

Peritoneal structures: No evidence of free air or free fluid. No masses. The omentum and small bowel mesentery are normal.

Retroperitoneum: No focal retroperitoneal abnormality is seen.

Abdominal wall: The visualized portions of the abdominal wall are within normal limits.

CT PELVIS:

Urinary bladder: The urinary bladder is distended with a smooth thin wall. No focal abnormalities are seen. No posterior filling defects are seen on delayed phase imaging.

Soft tissues: No other significant abnormalities in the pelvic structures. No free fluid or lymphadenopathy. The ischiorectal fossa and inguinal regions are normal.

Bones: No significant abnormalities in the bony pelvis.

IMPRESSION:

1. Grade 3 Spleen Lac

EXAMINATION: CT-EXT LWR LEFT WO CON

DATE OF EXAM: 11/17/2017

DEMOGRAPHICS: 7 years old Female

INDICATION: History: Lt Tib/fib fx. Number of Series/Images: 9.

COMPARISON: none

TECHNIQUE: Contiguous axial slices of the left lower extremity were submitted without IV administration of contrast. Additional coronal and sagittal reformatted images were submitted.

DOSE OPTIMIZATION: CT radiation dose optimization techniques (automated exposure control, and use of iterative reconstruction techniques, or adjustment of the mA and/or kV according to patient size) were used to limit patient radiation dose.

FINDINGS:
CT Left LOWER EXTREMITY:

Mildly displaced fracture through the medial malleolus, closed and displaced Lt Fbiula Fx, Bi-malleolar, closed. There is also apposition of the fracture fragments of approximately 70 mm. The imaged Left hip and knee joints appear otherwise intact. No obvious focal hematoma or fluid collection identified. No discrete soft tissue mass or radiopaque foreign body. Residual contrast is seen in the imaged urinary bladder.

IMPRESSION:

1. Mildly displaced fracture through the medial malleolus, closed and displaced Lt Fbiula Fx, Bi-malleolar, closed.

Study Result

PROCEDURE: XR-TRAUMA DISTAL RADIUS, RIGHT

DATE OF EXAM:

DEMOGRAPHICS: 7 years old Female

INDICATION: Trauma History: mva, Left tib/fib fx, Spleen Lac, Rt Distal Radius Forearm Lac. Number of Series/Images: 4.

COMPARISON: No existing relevant imaging study corresponding to the same anatomical region is available.

FINDINGS:
4 views of the Right Radius were obtained. There is acute Rt Distal Radius forearm lac with no fractures identified

IMPRESSION:

Medications Ordered/Given During ED Visit:

Current Facility-Administered Medications

Medication	Dose	Route	Frequency	Provider	Last Rate	Last Dose
Ancef						

Procedures: Attempted closed reduction of Lt Tib/Fib Fx under conscious sedation, failed attempt. See conscious sedation documentation.

Diagnosis: GR3 Spleen Lac, L tib/fib fxs, Mult Abras, Mult Contusions, R Radius Forearm lac

Medical Decision Making: transfer patient to Level 2 Pediatric Trauma Center, Rowboat Children's Hospital.

Disposition: Transfer

Man in Black Medical Center

Level III Trauma Center

ORTHOPEDIC SURGERY CONSULT/CONSCIOUS SEDATION

Reason for Consult: left distal tib/fib fx

Assessment:

left distal tib/fib fracture

Plan:

Review imaging
Sedated with ketamine under the supervision of the ER
Closed reduction with the help with the C arm-unsuccessful
Transfer to Pediatric Trauma Center, Rowboat Children's Hospital

Orthopedic specific Exam:

left leg:
obvious deformity, TTP at fracture site
NV intact distal to injury
motor intact to distal extremity
compartments soft
cap refill <2 sec

HPI: Ramona Kash is a 7 y.o. female who presents with left distal tib/fib fracture from MVC.

Primary Care Physician: MD

Allergies:

Allergies

Allergen	Reactions
• none	

Outpatient Meds:

Prescriptions Prior to Admission

(Not in a hospital admission)

Past Medical History:
No past medical history on file.

Past Surgical History:
No past surgical history on file.

Social History:

Social History
Social History

Social History

• Marital status:	Single

Spouse name:	N/A
• Number of children:	N/A
• Years of education:	N/A

Occupational History

- Not on file.

Social History Main Topics

• Smoking status:	Not on file
• Smokeless tobacco:	Not on file
• Alcohol use	Not on file
• Drug use:	Not on file
• Sexual activity:	Not on file

Other Topics | Concern

- Not on file

Social History Narrative

Family History:
No family history on file.

Review of Systems:
Left leg pain

No F/C, no HA/changes in vision, no CP/palpitations, no SOB, no N/V, no abd pain, no diarrhea/constipation, no melena/hematochezia, no dysuria/hematuria, no LE edema B/L

Physical Exam:

Vitals
Vitals:

BP:	124/56	118/70		108/78
Pulse:	120	112	124	84
Resp:	24	22	25	24
Temp:				
TempSrc:				
SpO2:	98%	100%	100%	100%
Weight:				
Height:				

Gen: Age appropriate. Alert and oriented x 3, no acute distress
HEENT: oropharyngeal airway patent
Neck: trachea midline, no JVD
CV: Appropriate perfusion to distal extremities B/L
Resp: Equal chest wall excursion B/L, no chest wall ttp, no signs of accessory muscle use for respirations
Abd: soft, no mass, tender LUQ
Neuro: no motor or sensory deficits to UE or LE B/L
Skin: Clean, dry, intact, no signs of rash/ecchymosis/open wound besides that noted in MSK exam
OMM Exam: There are no abnormal curves appreciated on spinal exam of cervical/thoracic/lumbar spines including kyphosis/lordosis and scoliosis. Asymmetry, tissue texture change, restricted motion and tenderness to palpation to left wrist pain.

Labs:
CBC/COAGS
No results for input(s): WBC, HEMOGLOBIN, HCT, PLT, INR, PTT in the last 72 hours.

Invalid input(s): PT

BMP
No results for input(s): NA, K, CL, CO2, BUN, CREATININE, GLU, PHOS, ALBUMIN, MG in the last 72 hours.

Invalid input(s): CA

Imaging: left **distal tib/fib fracture**

PROCEDURE: Reduction and splinting

ANESTHESIA: Local with IV conscious sedation; IV NS with #20 Left AC

GROSS PATHOLOGY: None

PROCEDURE:
The indications for the procedure include malreduced distal tib/fib fracture and an unprotected extremity. The patient remained in the ED and was sedated with ketamine under conscious sedation

The mini-C arm was utilized to evaluate the both bone fracture. The reduction was attempted and visualized in the AP and lateral, which was unsuccessful

Electronically signed
Maybelle Seeger 11/17/2017

Orthopedic Surgery Resident

Revision History

13:53	Outpt Procedural Sedation	Pre-Sedation Confirmation Physician H&P Complete: Other (Comment) Date of Last PO Intake: 11/17/2017	Informed Consent Obtained: (ER) Time of Last PO Intake: 1000
		Preprocedure Aldrete Activity: Able to move four extremities voluntarily or on command Circulation: Blood pressure within 20% of preanesthesia level Color: Pink Time Out coordinated per Dr. Seeger Procedure to be Performed:: closed reduction l leg Correct side and site marked?: Yes	Respiration: Able to breath and cough freely Consciousness: Fully awake Aldrete Score: 10 Correct patient identity?: Yes Site mark visible during time out?: Yes

		Agreement on procedure to be done?: Yes	Correct patient position?: Yes	
		Relevant images properly labeled and displayed?: Yes	Pre-op Antibiotics Given Or Available?: N/A	
		Physician(s) full name present for Time Out: Dr. Seeger	RN full name present for Time Out: kim	
		Procedure Times		
		IN Room Time: 16:41	Start Time: 16:45	
		Procedure Preparation		
		Cautery Used?: No		
		Sedation Vital Signs		
		Temp: 98.2 °F (36.8 °C)	Temp Source: Oral	
		Heart Rate: 83	Resp: 10	
		BP: 135/77	SpO2: 100 %	
		Cardiac Rhythm: ST		
		Oxygen Therapy		
		SpO2: 100 %	O2 Device: Nasal cannula	
		Conscious Sedation Procedure Medications		
		Ketamine: 80mg		
		Aldrete Postprocedure		
		Respiration: Able to breath and cough freely	Blood Pressure: Blood pressure within 20% of preanesthesia level	
		Consciousness: Fully awake	Aldrete O2 Saturation: >92% on room air	
		Activity: Able to move four extremities voluntarily on command	Aldrete Temp: Normal 36 - 38 cel.	
		Aldrete N/V: Swallow some fluid	Aldrete Pain: Pain, discomfort, unrelieved by medication	
		Aldrete Surgical Site: No drainage/No wound present	Aldrete Stage 1 Recovery Score: 10	
		Aldrete Stage II Recovery: 17		
	Outpt Procedural Sedation	Preprocedure Aldrete		
		Activity: Able to move four extremities voluntarily or on command	Respiration: Able to breath and cough freely	
		Circulation: Blood pressure within 20% of preanesthesia level	Consciousness: Arousable on calling	
		Color: Pink	Aldrete Score: 9	
		Sedation Vital Signs		
		Heart Rate: 112	Resp: **0**	
		BP: **164/97**	SpO2: 100 %	
		Oxygen Therapy		
		SpO2: 100 %		
14:03	Custom Formula Data	Other flowsheet entries		RN
		Dias BP %ile: **100 %**	Sys BP %ile: **100 %**	
14:07	Outpt Procedural Sedation	Sedation Vital Signs		
		Heart Rate: 124	Resp: 25	
		SpO2: 100 %	BP: 124/56	
		Oxygen Therapy		
		SpO2: 100 %		
		Conscious Sedation Procedure Medications		
		Ketamine: 20mg		

Get Rhythm EMS Sheet
RUN REPORT
Prehospital Patient Care Chart

INCIDENT NUMBER	EMS RESPONSE NUMBER	CALL SIGN	VEHICLE #	INCIDENT DATE
123-456				11/17/2017

INCIDENT ADDRESS	INCIDENT CITY	INCIDENT STATE	INCIDENT ZIP CODE
Big River Road	Jackson	Ohio	51503

INCIDENT COUNTY
Folsom

INCIDENT LOCATION TYPE See Ref. Sheet
Street

COMPLAINT REPORTED BY DISPATCH See Ref. Sheet

PRIMARY PAYMENT See Ref. Sheet

LEVEL OF CARE - UNIT
- ☐ BLS, EMR
- ☐ BLS, EMT
- ☐ BLS, AEMT
- ☐ ALS, AEMT
- ☐ ALS, Paramedic
- ☐ ALS, Nurse
- ☐ ALS, Physician
- ☐ Specialty Critical Care

INCIDENT/PATIENT DISPOSITION
- ☐ Treated, Transport EMS
- ☐ No Patient Found
- ☐ Treated, Transferred care
- ☐ Cancelled
- ☐ No Treatment Required
- ☐ Pt Refused Care
- ☐ Treated & Released
- ☐ Dead at Scene
- ☐ Treated, Transported Private Vehicle
- ☐ Treated, Transported Law Enforcement

EMERGENCY MEDICAL DISPATCH PERFORMED
- ☐ No
- ☐ Yes w/pre-arrival instructions
- ☐ Yes w/out pre-arrival instructions
- ☐ Yes Unk if pre-arrival instructions given

TYPE OF SERVICE REQUESTED
- ☐ 911 Response
- ☐ ED to ED Transfer
- ☐ Intercept
- ☐ Mutual Aid

PRIMARY ROLE OF THE UNIT
- ☐ Transport
- ☐ Non-transport
- ☐ Supervisor
- ☐ Rescue

LEVEL OF SERVICE
- ☐ BLS, Emergency
- ☐ ALS, Level 1 Emergency
- ☐ ALS, Level 2
- ☐ Specialty Care Transport
- ☐ Helicopter
- ☐ Not Applicable

 # OF PATIENTS ON SCENE
- ☐ Single
- ☐ None
- ☐ Multiple

MASS CASUALTY
- ☐ Yes
- ☐ No

PATIENT LAST NAME	PATIENT FIRST NAME	MI
Krash	Ramona	

PATIENT ADDRESS ☐ SAME AS INCIDENT	PATIENT CITY	PATIENT STATE	PATIENT ZIP CODE
	Jackson	Ohio	51503

AGE	DATE OF BIRTH	GENDER	RACE
7 year old	10-10-10	☐ Female ☐ Male	Hispanic

CURRENT MEDICATIONS	ALLERGIES	PERTINENT HISTORY
None	None	None

INJURY PRESENT
- ☐ Yes
- ☐ No

CAUSE OF INJURY See Ref. Sheet
MVC

TYPE OF INJURY
- ☐ Blunt
- ☐ Penetrating
- ☐ Burn
- ☐ Not Known

ALCOHOL/DRUG USE INDICATORS
- ☐ None
- ☐ Pt admits to drug use
- ☐ Smell of alcohol on breath
- ☐ Pt admits to alcohol use
- ☐ Alcohol and/or drug paraphernalia at scene

CHIEF COMPLAINT
Multiple Trauma Victim, spleen injury, tib/fib fxs, radius open dislocation

CONDITION CODE See Ref. Sheet

CHIEF COMPLAINT ANATOMIC LOCATION
- ☐ Abdomen
- ☐ Extremity Lower
- ☐ General/Global
- ☐ Chest
- ☐ Back
- ☐ Extremity Upper
- ☐ Head
- ☐ Neck
- ☐ Genitalia

CHIEF COMPLAINT ORGAN SYSTEM
- ☐ CNS/Neuro
- ☐ OB/GYN
- ☐ Pulmonary
- ☐ Global
- ☐ Renal
- ☐ Cardiovascular
- ☐ Psych
- ☐ Skin
- ☐ Musculoskeletal

CARDIAC ARREST
- ☐ Yes, Prior to Arrival
- ☐ Yes, After Arrival
- ☐ No

RESUSCITATION
- ☐ Defibrillation
- ☐ Ventilation
- ☐ Chest Compressions
- ☐ None-DOA
- ☐ None-DNR
- ☐ None-Signs of life

CAUSE OF CARDIAC ARREST
- ☐ Presumed Cardiac
- ☐ Respiratory
- ☐ Unknown
- ☐ Trauma
- ☐ Electrocution
- ☐ Drowning
- ☐ Other

USE OF SAFETY EQUIPMENT
- ☐ N/A
- ☐ Lap Belt
- ☐ Shoulder Belt
- ☐ Protective Clothing
- ☐ Not Known
- ☐ Helmet Worn
- ☐ Protective Non-Clothing Gear
- ☐ Other
- ☐ Child Restraint
- ☐ Eye Protection
- ☐ Personal Floatation Device

AIRBAG DEPLOYMENT
- ☐ None Present
- ☐ Deployed Front
- ☐ Not Deployed
- ☐ Deployed Side
- ☐ Deployed Other

BARRIERS TO EFFECTIVE CARE
- ☐ Development Impaired
- ☐ Physically Impaired
- ☐ Unattended/Unsupervised
- ☐ Hearing Impaired
- ☐ None
- ☐ Physical Restraint
- ☐ Unconscious
- ☐ Language
- ☐ Speech Impaired

RESPONSE MODE / **TRANSPORT MODE**
- ☐ ← Lights/Sirens → ☐
- ☐ ← No Lights/No Sirens → ☐
- ☐ ← Initial Lights/Sirens Downgraded to no Lights/Sirens → ☐
- ☐ ← Initial No Lights/Sirens Upgraded to Lights/Sirens → ☐

Initial Call for Help	16:55	Unit Left Scene	17:18
Unit Notified	16:55	Patient arrived at Destination	17:32
Unit En Route	16:58	Transfer of Patient Care	17:38
Arrive on Scene	17:10	Incident Completed	17:45
Arrived at Patient	:		

PRIOR AID See Ref. Sheet

PERFORMED BY	MEDICATIONS/ PROCEDURES	OUTCOME

INCIDENT NUMBER	UNIT ID	INCIDENT DATE

TRAUMA TRIAGE CRITERIA

- ☐ 2nd/3rd burn >10% BSA or face/feet/hand/genital/airway
- ☐ Amp prox to wrist/ankle
- ☐ Decreasing LOC
- ☐ GCS Motor >4
- ☐ GCS Total ≥13
- ☐ Head/neck/torso crush
- ☐ Extremity inj w/neurovasc comp
- ☐ Extremity crush
- ☐ Torso inj w/pelvic fx
- ☐ Flail chest
- ☐ Torso inj w/abd tender/ distended/seatbelt sign
- ☐ LOC ≥5 min
- ☐ Mech of inj
- ☐ Did not meet any triage criteria
- ☐ Pen inj head/neck/torso
- ☐ Pen inj prox to knee/elbow w/neurovasc comp
- ☐ Spinal cord inj
- ☐ Special Considerations
- ☐ 2+ prox humerus/femur fxs

ADULTS ONLY

- ☐ Pulse >120 w/hemor shock
- ☐ Tension pneumothorax
- ☐ Resp <10 or >29
- ☐ Required intubation
- ☐ SysBP <90, or no radial pulse w/carotid pulse

PEDS ONLY

- ☐ Poor perfusion
- ☐ Resp distress/failure

SYMPTOMS PRIMARY=P ASSOCIATED=A

P	A	
☐	☐	None
☐	☐	Bleeding
☐	☐	Breathing
☐	☐	Changes in Responsiveness
☐	☐	Choking
☐	☐	Death
☐	☐	Device/Equip Prob
☐	☐	Diarrhea
☐	☐	Drainage/Discharge
☐	☐	Fever
☐	☐	Malaise
☐	☐	Mass/Lesion
☐	☐	Mental/Psych
☐	☐	Nausea/Vomiting
☐	☐	Pain
☐	☐	Palpitations
☐	☐	Rash/Itching
☐	☐	Swelling
☐	☐	Transport Only
☐	☐	Weakness
☐	☐	Wound

PROVIDER IMPRESSION PRIMARY=P SECONDARY=S

P	S	
☐	☐	Abd pain
☐	☐	Airway obstruct
☐	☐	Allergic rxn
☐	☐	Altered LOC
☐	☐	Behavior/psych
☐	☐	Cardiac arrest
☐	☐	Cardiac arrhythmia
☐	☐	Chest pain
☐	☐	Diabetic
☐	☐	Electrocution
☐	☐	Hyperthermia
☐	☐	Hypothermia
☐	☐	Hypovolemia/shock
☐	☐	Inhalation/toxic gas
☐	☐	Inhalation/smoke
☐	☐	Death
☐	☐	Poisoning/drug OD
☐	☐	OB/delivery
☐	☐	Resp arrest
☐	☐	Resp distress
☐	☐	Seizure
☐	☐	Sexual assault/rape
☐	☐	Stings/bites
☐	☐	Stroke/CVA
☐	☐	Syncope
☐	☐	Injury
☐	☐	Vag bleed

MEDICATIONS

TIME	MEDICATION	DOSE	ROUTE	REACTIONS See Ref. Sheet
17:18	Fluids	125 mc/hr KVO	Lac piv	
:				
:				
:				
:				

PROCEDURES

TIME	PROCEDURE	# ATTEMPTS	SUCCESSFUL	COMPLICATIONS See Ref. Sheet
:	PIV LAC in referring ED	1	☐ YES ☐ NO	
:			☐ YES ☐ NO	
:			☐ YES ☐ NO	
:			☐ YES ☐ NO	
:			☐ YES ☐ NO	

VITAL SIGNS See Ref. Sheet

TIME	PULSE	SYS BP	DIA BP	RESP	O2 SAT	GCS EYE	GCS VERBAL	GCS MOTOR
17:20	98	98	60	16	99/RA	4	5	6
:								
:								
:								
:								

ADV DIRECTIVE

- ☐ State DNR Form
- ☐ Other Healthcare DNR
- ☐ Family Request DNR (no form)
- ☐ None
- ☐ Living Will
- ☐ Other

DESTINATION

Rowboat Children's Hospital, Level 2 Pediatric Trauma Center

TYPE OF DESTINATION

- ☐ Hosp ED/OR/L&D
- ☐ Other EMS (air)
- ☐ Other EMS (ground)
- ☐ Other

REASON FOR CHOOSING DESTINATION

- ☐ Closest
- ☐ Diversion
- ☐ Family Choice
- ☐ Insurance
- ☐ Law Enforcement Choice
- ☐ On-line Med Control
- ☐ Other
- ☐ Pt. Choice
- ☐ Pt. Physician's Choice
- ☐ Protocol
- ☐ Specialty Resource Center

ED DISPOSITION

- ☐ Admit-floor
- ☐ Admit-ICU
- ☐ Death
- ☐ Discharge
- ☐ Transfer-other hosp

HOSPITAL DISPOSITION

- ☐ Death
- ☐ Discharge
- ☐ Transfer-other hosp
- ☐ Transfer-nursing home
- ☐ Transfer-other
- ☐ Transfer-rehab

NARRATIVE

HX: 7yof involved in single vehicle MVC, lap belt restrained passenger in middle row behind driver's seat of family's van. Reported vehicle burst into flames just after patient was removed. Patient transported to level 3 TC via local Fire and EMS

Get Rhythm Helicopter dispatched to level 3 trauma center, Man in Black Medical Center for transport of multiple trauma pediatric patient. Reported patient has spleen lac, lt tib/fib fxs, rt radius open dislocation, multiple contusions, abrasions, small forearm lac.

Patient PIV LAC maintained with fluids

Patient transported to Rowboat Children's Hospital without incident. Vital signs remained stable throughout transport HR 98/RR 16/BP 98/60/ PULSE OXIMETRY 99 on room air/GCS TOTAL 15

CREW MEMBER	CREW MEMBER	CREW MEMBER
CREW MEMBER	CREW MEMBER	CREW MEMBER

Rowboat Children's Hospital

Ramona Krash 7yo female
Birthdate: 10/10/2010
MRN 11111111

Date: 11/17/2017 Patient Arrival Time: 17:32

N/A Pre-Hospital Treatment		
Transporting Ambulance **Get Rhythm Helicopter**		
O2 @ _L/min/	IV: Needle size_#20 LAC	X_Backboard
NC NRB Ambu	NS	Long___ Short___ Ked___
Airway	Medications	Scoop
Oral Nasal Other	_____	Bilateral Head Supports
ET tube # _____ @ cm	C-Collar on: Yes_X___ No	Splint on
	_____	Ice on
CPR started @ (time)	_____	Dressing
		Other

Date of Injury: 11/17/2017 Time of Injury: UNK Pre-hospital trauma team alert notification: X Yes No

Hospital Trauma Team Activation Yes X No____ Time of Trauma Team Activation: 16:55

Trauma Team Members		
Team members notified:	Time Called	Time Arrived
‰ Nurses x		
‰ Physician / CNP / PA		
‰ Lab		
‰ X-ray		
‰ Other		

Type of Vehicle	
X Car	Pedestrian
Truck	ATV
Motorcycle	Boat
Bicycle	
Other _____	

Mechanism of Injury

Speed of vehicle MPH _____	Rollover
Number of vehicles	Ejected
1 2 3 >3	Rearend
Steering wheel deformity	T-Bone
Starred windshield	Head on

Restraint Devices	
X Lap belt	Airbag deployed
Shoulder belt	Helmet
Car seat	Unrestrained

Fall	Penetrating	Blunt	Thermal	Other
‰ Fell from: _____	‰ GSW _____	‰ Assault _____	‰ Burn _____	‰ Hanging _____
	‰ Stabbing _____	‰ Crush _____	‰ Heat exposure	‰ Near drowning
Height_____ ft.	‰ Other _____	‰ Other _____		
			‰ Cold exposure	‰ Animal related

Initial Assessment

AIRWAY

X Patent
‰ Oral Airway
‰ Nasal Airway
‰ ET _____
‰ Trach
‰ Crico

‰ Suctioning
‰ Bag Mask
‰ O2 __2_____ L.
Comments
_____
_____

BREATHING

Spontaneous			Respiratory Effort	
R	L		X **Normal**	‰ Agonal
X	X	Lung sounds	‰ Shallow	‰ Nasal flaring
		Clear	‰ Stridor	‰ Tachypnea
		Rales	‰ Dyspnea	‰ Grunting
		Rhonchi/Wheezes	‰ Retracting	‰ Absent
		Decreased	‰ Intercostal	‰ Paradoxical
		Absent	‰ Substernal	‰ Cough

Smoker ‰ Yes X No ‰ Unk

CIRCULATION

Capillary Refill: ‰ None ‰ Delayed (> 2 sec) X **Normal** (< 2 sec)
Pulses Present: ‰ Carotid ‰ Femoral ‰ Radial ‰ Pedal
Palpated Pulse X **Regular** ‰ Irregular
Heart tones X **Audible** ‰ Absent
Jugular Vein Distension X **No** ‰ Yes
Bleeding X **Controlled** ‰ Uncontrolled X NA
Skin Color X Pink ‰ Dusky
‰ Pallor ‰ Cyanotic
‰ Flushed ‰ Mottled

DISABILITY

Glasgow Coma Score		Initial	Disch
Eye Opening			
Spontaneously	4		
To Speech (Shout)	3		
To Pain	2	4	
No Response	1		
Verbal Response			
Oriented (Coos, Babbles)	5		
Confused (Consolable, Cry)	4		
Inappropriate Words (Persistent Cries, Screams)	3		
Incomprehensible Words (Grunts, Restless)	2		
No Responses	1	5	
Motor			
Obeys (Spontaneous)	6		
Localized Pain	5		
Withdrawal to Pain	4		
Flexion to Pain (Decorticate)	3		
Extension to Pain	2		
No Response to Pain	1	6	
Total GCS Score @17:35		**15**	

Allergies: none
Tetanus: _ LMP:_____ Wt: _____

Procedures

Time	Procedure	Results
	ET Tube _____ Combitube ____	Size _____ Secured @ _____ cm FiO2 %
PTA	Central Line/ IV PIV LAC #20	Size 20 Fr Site LAC Solution_
17:38	Warming Measures	X Fluids ‰ Mechanical ‰ Bair Hugger X Blankets
	NG Tube	Size _____ Color _____
	Foley / Quick Cath	Size _____ Color
PTA	Neck immobilization C-Collar Applied: PTA _____	CMS: Before _____ After _____
	Splinting _____ _____	Location: _____

Area of Injury

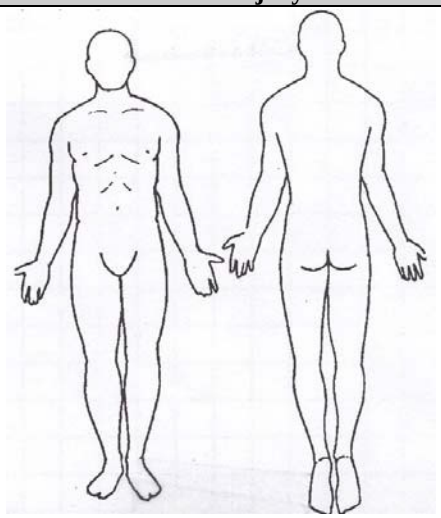

A = Abrasion	Fc = Closed Fracture	OW = Open Wound
B = Burns	Fd = Dislocation	P = Paralysis
C = Crepitus	Fo = Open Fracture	S = Edema
D = Deformity	**L = Laceration**	Ta = Total Amputation
E = Ecchymosis		Na = Near Amputation

Secondary Assessment

Head/Scalp	Eyes	Mouth	Ears
X Intact ‰ Laceration ‰ Abrasions ‰ Bruising ‰ Rash ‰ Burns ‰ Pain ‰ Battle Signs	X PEARL ‰ Raccoon eyes ‰ EOMS follows ‰ Visual Acuity OD ____/_ ___ OS ____/____	‰ Intact ‰ Teeth ‰ Missing teeth ‰ Dentures intact ‰ Comments_____	X No drainage ‰ Drainage ‰ Right ‰ Left ‰ Clear ‰ Clear ‰ Blood ‰ Clear

Neck	Chest	Heart Sounds
‰ Intact ‰ Swelling ‰ Trachea midline ‰ Trachea deviated ‰ Sub-q emphysema ‰ Difficulty swallowing X C-Collar ‰ Pain	X Symmetrical ‰ Asymmetrical ‰ Paradoxical movement Location _____ ‰ Crepitus Location_____ ‰ Chest Pain Location _____ Time of onset _____ Activity @ onset _____ ‰ Flail chest ‰ Other _____	X Present ‰ Distant ‰ Absent

Abdomen / Pelvis / GU

Abdomen	Bowel Sounds	Pelvis
‰ Soft ‰ Nontender X Tender ‰ Distended ‰ Rigid ‰ Last Intake: Food breakfast Liquid _____ ‰ Comments: _____	X Present ‰ Absent ‰ Hyperactive ‰ Hypoactive	X Intact ‰ Pain _____ ‰ Blood at meatus _____ ‰ Blood at rectum _____ ‰ Instability _____

Posterior	Extremities
X Intact ‰ Deformity ‰ Pain ‰ Comments LUQ _____	‰ Intact ‰ Fracture ‰ Pain X Deformity X Comments Lt Tib/Fib Fx with OCL splint intact, Rt Forearm 3cm _____

Time	Temp	P	R	BP	SaO2	O2 L/min	Pupil Reaction (S-slow, B-brisk, F-fixed, C-closed by swelling; U-unequal, D-dilated, = - Equal)		Pain Scale 0-10 Pain		Comments
									Scale	Type	
17:35	98.9	100		98/59	99	RA	Right	Left	4		
17:45		92	20	95/55	100	RA	=	=	5		Unassisted respiratory rate
18:00	98.6	88	22	96/52	100	RA	=	=	5		
				/							
				/							
				/							
				/							
				/							
				/							
				/							
				/							
				/							

Medications Given

Medication	Dose	Route	Time Given	Initials
NS	80ml	IV	1815	SM
Zofran	4mg	IV	1812	SM

Input				**Output**			
Source	**Prior to Arrival**	**ED**	**Total**	**Source**	**Prior to Arrival**	**ED**	**Total**
IV Fluids	PTA			Urine			
				Emesis			
				Chest Tube			
				Other			
Blood							
Fresh Frozen Plasma							

Nurse Notes: Patient arrived via helicopter after single MVC where patient was the rear passenger with lapbelt only restraint. Patient is transferred from Level 3 trauma center, Man in Black Medical Center. FAST exam was positive, CT of Abdomen at Level 3 facility indicates moderate GR3 spleen laceration. All imaging to be re-read here. Patient was evaluated by the trauma team and discharged from ED at 1900.

RN Signature: _____

FINAL DISPOSITION: Patient's order to admit to the floor at 18:15 11/17/17 written by Dr. Damon Fielder.

Patient will be taken to the OR in the morning by Orthopaedics for ORIF of Lt Tib/Fib Fxs

Name: Ramona Krash	Date/Time of Admission: 11/17/2017
CSN: 11111111	Attending Provider: Dr. Damon Fielder
Room/Bed: ED 14/14A	DOB: 10/10/2010 7 y.o. female

FOCUSED ASSESSMENT WITH SONOGRAPHY FOR TRAUMA (FAST).

INDICATION: Blunt thoracoabdominal trauma

PROCEDURE IN DETAIL: The scan was performed using either a phased array or curvilinear transducer. Using the curvilinear transducer, a coronal plane of the right upper quadrant of the abdomen and the right chest was obtained and was negative for blood in the right chest, in Morison's pouch, or the right paracolic gutter. A sub-xiphoid or parasternal long axis view of the heart was obtained. There were no signs of pericardial effusion or cardiac tamponade. Next, a coronal plane of the left upper quadrant of the abdomen including left chest was obtained and was no for blood in the left chest, splenorenal space, in the left pericolic gutter. Finally, the urinary bladder was insonated in the sagittal and transverse planes and there was possible evidence of free intraperitoneal fluid posterior or lateral to the bladder. The patient tolerated the procedure well with no complications.

CONCLUSION: This was a negative FAST exam for free intraperitoneal blood, hemothorax, or hemopericardium.

HISTORY & PHYSICAL

Rowboat Children's Hospital

Level II Pediatric Trauma Center

Name: Ramona Krash	Date/Time of Admission: 11/17/2017
CSN: 11111111	Attending Provider: Dr. Damon Fielder
Room/Bed: ED 14/14A	DOB: 10/10/2010 7 y.o. female

TRAUMATIC EVENT: MVC

Mode of Arrival: helicopter

☐ Trauma I ☐ Trauma II ☐ Trauma Consult ☐ Trauma Transfer From:

HPI: Ramona Krash7 y.o. female who arrived to Rowboat Children's Hospital Emergency Department following an MVC. Pt was wearing a lapbelt only. CT with IV contrast of the abdomen and pelvis was obtained and demonstrated GR3 spleen lac.

Patient Name: Krash, Ramona
Date:

Mechanism of Injury: MVC passenger

Injuries: GR3 Spleen Lac, L tib/fib fxs, Mult Abras, Mult Contusions, R Radius Fx w/tendon lac and RFA lac

Other Medical Problems: none

Incidental Findings: None

Admission Plan of Care: OR for reduction of tib/fib fx, non-operative treatment for GR3 Splenic Lac

---

Chief Complaint (CC): Multiple Trauma

History of Present Illness (HPI): 7yof, lap belt only restrained middle backseat passenger of van involved in MVC with loss of control and down an embankment, landing on its top, reported patient's vehicle engulfed in flames. Transport via Helicopter, 'Get Rhythm Air Medical Services'

Past Medical History (PMH): none

Past Surgical History: none

Social history:

- **Smoking status:** **No**
- **Smokeless tobacco:** **No**
- **Alcohol use:** **No**

Social History Main Topics

- Smoking status: Never Smoker

• Smokeless tobacco:	Never Used
• Alcohol use	No
• Drug use:	No
• Sexual activity:	Not on file

Family history: Not on file

Medications: None

Allergies:
Allergies not on file

REVIEW OF SYSTEMS [List positives and pertinent negatives]**:**
Constitutional Symptoms:
Eyes: NEGATIVE
Ears, Nose, Mouth, Throat: ENT EXAM NORMAL
Cardiovascular: S1 AND S2 NORMAL
Respiratory: NORMAL BREATH SOUNDS, NO RESPIRATORY DISTRESS, NO WHEEZING
Gastrointestinal: Abdomen soft with guarding, tenderness with concern for organ injury
Genitourinary:
Musculoskeletal: LLE obvious deformity, RUE obvious deformity, distal pulses are palpable in lt foot and RUE, Neuro intact at distal Lt Lower Extremity, otherwise moving extremities appropriately. RUE FA 3cm lac with tendon involvement.

Skin/Breast: Normal coloration and turgor, no rashes, no suspicious skin lesions noted. RUE FA lac with tendon involvement

Neurological: No motor or sensory abnormalities
Psychiatric: Affect normal, Mood normal , Judgment normal.
Endocrine:
Hematologic/Lymphatic:
Allergic/Immunologic: NONE

PHYSICAL EXAM:
Initial Vital Signs
BP 113/60 mmHg | **Pulse** 85 | **RR** 20 | **Temp:**xx | **Ht** not on file | **Wt** 18.6 kg (x lb) | **SpO2** 100%

PRIMARY SURVEY
AIRWAY: Patent, trachea midline. Phonation is normal.
BREATHING: Symmetric chest rise and fall. Breath sounds present bilaterally.
CIRCULATION: Pulses 2+ throughout.
DISABILITY: Moves extremities normally x 4. No lateralizing neurologic signs. Pupils 3 mm equal and reactive bilaterally.
Glascow Coma Scale:
EYES = 4
VERBAL = 5
MOTOR= 6
GCS = 15

SECONDARY SURVEY
GENERAL: AOx3, in no acute distress
HEAD/FACE, EYES, ENT: Head atraumatic, ENT exam normal, conjunctivae/corneas clear. PERRL, EOM's intact. No battle signs or raccoon eyes present
NECK: Supple without obvious injury

CHEST/RESPIRATORY: Resp: No chest wall deformities or tenderness, resp effort normal. No wheezing, rhonchi or rales
CVS: RRR, no murmurs, gallops or rubs
ABDOMEN/GI: Abdomen soft with guarding, tenderness with concern for organ injury, FAST Exam pos for some intraperitoneal blood
PELVIS: stable with no gross deformities, without obvious tenderness to palpation
GU and RECTAL: no gross hematuria, no trauma or blood indicated
BACK / TLS SPINE: No obvious tenderness or bony step off deformities
EXTREMITIES/MSK: LLE obvious deformity, RUE obvious deformity, distal pulses are palpable in lt foot and RUE, Neuro intact at distal Lt Lower Extremity, otherwise moving extremities appropriately. RUE FA 3cm lac with tendon involvement.
SKIN: Normal coloration and turgor, no rashes, no suspicious skin lesions noted. RUE FA lac with tendon involvement
NEURO: No motor or sensory abnormalities
PSYCH: Affect normal, Mood normal , Judgment normal.

Laboratory Results:
Labs:

CBC/COAGS
Recent Labs-today

	1502	1503
WBC	--	9.1
HEMOGLOBIN	--	13.5
HCT	--	40.6
PLT	--	272
INR	1.1	--
PTT	23.0*	--

Imaging (if any) During ED Visit:

External Result Report

External Result Report

Study Result

```
EXAMINATION: CT-EXT LWR LEFT WO CON

DATE OF EXAM:  7/25/2017 3:44 PM

DEMOGRAPHICS: 7 years old Female

INDICATION:             History:  Lt Tib/fib fx. Number of Series/Images:  9.

COMPARISON: none
```

TECHNIQUE: Contiguous axial slices of the left lower extremity were submitted without IV administration of contrast. Additional coronal and sagittal reformatted images were submitted.

DOSE OPTIMIZATION: CT radiation dose optimization techniques (automated exposure control, and use of iterative reconstruction techniques, or adjustment of the mA and/or kV according to patient size) were used to limit patient radiation dose.

FINDINGS:
CT Left LOWER EXTREMITY:
Mildly displaced fracture through the medial malleolus, closed and displaced Lt Fbiula Fx, Bi-malleolar, closed. There is also apposition of the fracture fragments of approximately 70 mm. The imaged Left hip and knee joints appear otherwise intact. No obvious focal hematoma or fluid collection identified. No discrete soft tissue mass or radiopaque foreign body. Residual contrast is seen in the imaged urinary bladder.

IMPRESSION:

1. Mildly displaced fracture through the medial malleolus, closed and displaced Lt Fbiula Fx, Bi-malleolar, closed.

Study Result

PROCEDURE: XR-TRAUMA DISTAL RADIUS, RIGHT

DATE OF EXAM:

DEMOGRAPHICS: 7 years old Female

INDICATION: Trauma History: mva, Left tib/fib fx, Spleen Lac, Rt Distal Radius complete dislocation, open with Forearm Tendon Lac. Number of Series/Images: 4.

COMPARISON: No existing relevant imaging study corresponding to the same anatomical region is available.

FINDINGS:
4 views of the Right Radius were obtained. There is acute complete dislocation of the Rt Distal Radius Open Dislocation.

IMPRESSION:

1. There is acute complete dislocation of the Rt Distal Radius Open Dislocation and with Rt Forearm Tendon Laceration

Medications Ordered/Given During ED Visit:

Current Facility-Administered Medications

Medication	Dose	Route	Frequency	Provider	Last Rate	Last Dose

Ancef

Diagnosis: GR3 Spleen Lac, L tib/fib fxs, Mult Abras, Mult Contusions, R Radius Fx w/tendon lac and RFA lac

Medical Decision Making: Admit for surgical intervention of Lt Tib/Fib Fx

Disposition: Admit

Physician Discharge Summary

Patient ID **Ramona Krash**
7yo MVC

Admit date: 11/17/2017
Discharge date and time: 11/23/2017
Admitting Physician: Dr. Damon Fielder

Discharge Physician: Dr. Damon Fielder
Admission Diagnoses: GR 3 Spleen Lac, Lt Tib/Fib Fxs, Multiple Contusions, Multiple Abrasions, Rt FA Lac, 3cm

Discharge Diagnoses: Same as above

Admission Condition: fair

Discharged Condition: good

Indication for Admission: Patient sustained a GR 3 Spleen Lac and was treated non-operatively and remained hemodynamically stable throughout her inpatient stay. Patient taken to the OR for ORIF of Lt Tib/Fib Fxs. Sutures were done in the ED for the RFA lac. She was admitted to the hospital for medical optimization as well as surgical fixation of her Lt tib/fib fxs.
Hospital Course: She was admitted to the hospital for further work-up and treatment. On 11/18/2017 patient was taken to the operating room for open reduction internal fixation of the Lt Tib/Fib Fxs. Patient underwent the surgery without any apparent complications. Patient was then admitted back up to the floor. There she began to work with physical therapy as well as got her pain back under control. Over the next week she continued to work with physical therapy with good results and was able to be discharged on POD 5, 11/23/2017. Prior to discharge she was tolerating a diet, her pain was controlled on oral medications and was working well with therapy.

Consults:
Internal medicine
Discharge Exam:

Physical Exam	
General Appearance	alert, well appearing, and in no distress
Musculoskeletal	Dressing/incision c/d/i, staples in place, no erythema no drainage no swelling motor 5/5 in UE/LE BL DF/PF/EHL/FHL 5/5 sensation intact to light touch No focal sensory deficits Compartments soft/NT extremity well perfused, pulses palpable, capillary refill <3 seconds
Skin	Warm and dry

Disposition: Discharged home in good condition

Patient Instructions:
Discharge Medication List as of 11/23/2017 9:47 AM

START taking these medications

	Details
Zofran 4mg ODT	PRN
Tylenol 325 mg PO	Take 1 capsule by mouth every 4 hours as needed for pain.
Vicodin 5mg PO	Take ½ tablet every 6 hours for severe pain as needed.

Activity: activity as tolerated; per PT evaluation
Diet: regular diet
Wound Care: keep wound clean and dry; follow up for suture removal in 7 days
Follow-up with Dr. Fielder

OPERATIVE REPORT

DATE OF PROCEDURE: 11/17/2017

PRE-OPERATIVE DIAGNOSIS: Traumatic Subdural Hematoma with loss of consciousness

POST-OPERATIVE DIAGNOSIS: Left Temporal Subdural Hemorrhage with loss of consciousness, Brain compression and Left temporal skull fracture extending to Left Parietal bone, closed

PROCEDURE: Craniotomy, ICP placement

SURGEON: Dr. William Beck

FIRST ASSISTANT: John Kingsland

ANESTHESIA: General endotracheal intubation

HISTORY: Patient is a 43 year old male driver of a minivan that lost control and rolled down a four-foot embankment, flipping over and landing on its top. Patient was air lifted from scene. Patient was intubated on scene. Patient was showing signs of hemiparesis. Surgery was undertaken with decompression of the brain. There was no family available prior to emergent surgery.

OPERATIVE PROCEDURE: After anesthesia induction, a roll was placed under the left shoulder. The head was placed in a Mayfield head tongs and turned to the right and secured on the table. Next, a linear incision was midway between the ear and the midline of the left side over the parietal, incision was infiltrated with lidocaine and epinephrine. This was carried out to the periosteum.

Next, a retractor was placed, a burr hole was made over the fracture, and then a large craniotomy was turned. A moderate to large subdural hematoma was evacuated. The edges were packed with a thin layer of Gelfoam and thrombin and then sutures were placed in the periphery of the craniotomy. Additional sutures were placed and secured to the skull flap. The skull flap was put back together and secured using Stryker plates and screws. Galea was closed using 3-0 Vicryl and skin with 4-0 prolene in running interrupted fashion. Next, our attention was turned to the insertion of the Camino bolt, using drill bit from Camino kit, a burr hole was created and rinsed with saline. Next, the dura was opened using #11 blade to make a cruciate incision. Then the catheter tip was placed within the sheath and used to tunnel the catheter under the scalp toward the drill hole. The catheter was inserted and connected to the drainage system. The incision was properly closed using 4-0 prolene.
The patient was taken out of the Mayfield tongs, and taken to the NICU postoperatively in critical condition.

William Beck
D: 11/17/2017 22:13:45 T: 11/18/2017 08:32:12
Job #: 8125687 Doc #: 5879561

PROCEDURE SUMMARY:

Date: 11/17/2017
Location: OR 4
Anesthesia Start: 17:22
Anesthesia Stop: 19:16
Procedure: Craniotomy, ICP placement
Diagnosis: Subdural Hematoma
Surgeon: Dr. William Beck
Responsible Provider: Dr. Jack Penny
Anesthesia Type: General
ASA Status: 2

EVENTS:

DATE	TIME	EVENT
11/17/2017	17:22	Anesthesia start
	17:28	Induction – Patient intubated prior
	17:31	Anesthesia Ready
	19:13	Hand off to Receiving Nurse- NICU
	19:16	Anesthesia Stop

VITALS:

DATE	TIME	BP	PULSE	RESP	TEMP	SPO2
11/17/2017	17:16	130/90	105	16	36.4	98
	17:18	128/85	103	18	36.5	99
	17:20	129/83	103	20	36.1	100
	17:22	130/88	100	18	36.3	100
	17:24	125/85	99	20	36.6	99

CASE TRACKING EVENTS:

DATE	TIME	EVENT
11/17/2017	16:22	In Facility
	17:15	In Pre-procedure
	17:22	Anesthesia Start
	17:20	In Room
	17:25	Induction
	17:40	Procedure Start
	19:01	Procedure Closing
	19:01	Procedure Finish
	19:26	End of Periop Care

Intra-procedure I/O Totals:

INPUT:	
0.9% sodium Chloride Infusion	2000ml

OUTPUT:	
EBL (ml)	50

Walk the Line Hospital

1932 Sun Records Drive
Starkville City, OH 91203

CHEMISTRY REPORT

Patient: Krash, Jimmy **MRN :** 774859
DOB: 06/01/1974 **ENCOUNTER NO:** 5589658599

Date: 11/17/2017
Time reported: 17:02

Ethanol & Volatile Screen (blood and urine) Results:

	Units	Normal	Result
Ethanol (alcohol) Blood	Mg/dL	<10	10 (negative)
Ethanol (alcohol) percent	%		0.01

DISCHARGE SUMMARY

Patient Name: Krash, Jimmy
Account #: 5589658599
MR #: 774859
Admission Date: 11/17/2017
Discharge Date: 11/29/2017
Discharge Disposition: Orange County Rehab
Attending Physician: Dr. Jack Penny
Dictating Physician: Dr. Sue Riders
Admitting Diagnosis: Traumatic Subdural Hemorrhage, without loss of consciousness, initial encounter
Discharge Diagnosis:
Traumatic Subdural hemorrhage without loss of consciousness
Cerebral Edema
Left Temporal Skull Fracture, nondisplaced
Nasal Septum Fracture
Nasal Bone Fracture
Left Zygomatic Arch Fracture, nondisplaced
Left Clavicle Shaft Fracture
Lt AC joint Separation
Left Orbital Floor blowout fracture, comminuted
Brown Sequard Syndrome at T3 level
T3/ T4 dislocation
Consultations: Neurosurgery, Orthopedics, Oral Maxillofacial, Urology
Procedures: Craniotomy, ICP- Camino Bolt
Complications: NONE

Hospital Course: Patient is a 43 yo white male who was the driver of a van that was involved in a motor vehicle accident resulting in rollover in embankment. Patient arrived intubated via flight from scene. In the ED patient was activated as a Trauma Level 1, it was identified via chest x-ray that the OETT was resting in the right Mainstem and was retracted for proper airway management. A CT head, CT Face, CT Spine, CT abdomen and pelvis were all completed and subdural hemorrhage was identified. Neurosurgery evaluated patient in ED and decided to take patient straight to OR for craniotomy and IPC monitor placement. After OR procedure patient remained intubated and was admitted to the NICU. Orthopedics had also evaluated the patient in the ED. Patient was identified to have a left clavicle fracture and an AC separation. On day 1 post-op OMF was consulted and discussed to re-evaluate facial injuries after swelling subsides. On day 6, patients ICP monitor was removed. On day 6 patient was extubated without issues. On HOD 8 patient was transferred to Neuro stepdown. Patient was experiencing tingling sensation/ weakness on his left side of his body and no sensation on the right. Neurosurgery identified the patient as having Brown-Sequard Syndrome at the T3 level, where it was previously identified that the patient had a T3/T4 dislocation. On day 10 patient was experiencing shortness of breath and lost pulses, going into cardiac arrest. A code blue was called and CPR was initiated. Patient had ROSC with ACLS protocol. Pt was then transferred to the NICU. OMF evaluated and fractures were determined to be treated as an outpatient. Patient then spent 2 more uneventful days in the NICU and was then transferred to an LTAC.

Labs: No results for input in the last 24 hours

Radiology Results:

EXAM: CT Head w/ out contrast
Indication: suspected head injury
Technique: Multiple contiguous 5 mm axial images were obtained from the skull base to the vertex without the use of intravenous contrast.
Comparison: NONE
Findings: The ventricles and sulci are within normal limits. There is a 1.3cm thick left temporal subdural hemorrhage, showing a 4mm right midline shift. There is noted compression of the brain. There is also evidence of a left temporal skull fracture overlying the before mentioned subdural hemorrhage extending to the left parietal bone. There is no evidence of acute territorial infarct. The paranasal sinuses are well-aerated.
Impression: 1.3 cm SDH, Lt temporal w/ 4mm RT midline shift noted brain compression
Lt temporal skull fracture extending to Lt Parietal bone

EXAM: CT Chest, Abdomen and Pelvis with contrast
CLINICAL HISTORY: s/p MVA.
TECHNIQUE: Multiple axial, coronal CT images were obtained through the abdomen and pelvis after administration intravenous contrast material.
COMPARISON: NONE
FINDINGS: Lower Thorax: Images of the lung bases show no evidence of pleural or parenchymal mass. There are no pleural effusions. Chest: The ribs are all intact, the right clavicle is intact, and there is a fracture of the left clavicle shaft, with butterfly fragment, that appears comminuted. There is also a left acromioclavicular joint separation
Abdomen: Gallbladder and Bile Duct: There is no intra or extrahepatic biliary ductal dilatation.
The gallbladder is again noted to be markedly contracted and surrounded by fluid. Chronic cholecystitis is suspected Pancreas: The pancreas is of normal contour and attenuation characteristics.
Spleen: The spleen is normal.
Adrenals: There is no evidence of adrenal mass.
Kidneys and Ureters: Both kidneys demonstrate prompt and equal nephrograms. The kidneys are normal in size, shape and configuration. There evidence of a Grade 2 capsular Kidney contusion on the right. No renal or ureteral calculi are identified. There is no hydroureter or hydronephrosis. Pelvis: Bladder: There is no evidence of intrinsic or extrinsic bladder mass. Stomach and Bowel: No definite evidence for appendicitis. There is no bowel wall thickening. No evidence for small or large bowel obstruction. There is no evidence of abdominal ascites or lymphadenopathy. Peritoneum: Bones: The bony structures appear intact.
IMPRESSION:

1. Right Grade 2 capsular kidney contusion
2. Chronic cholecystitis is suspected
3. Left clavicle shaft fracture, with butterfly fragment, comminuted
4. Left Acromioclavicular joint separation

EXAM: CT Face w/ out contrast
Indication: Facial injury
Technique: A facial CT was performed utilizing contiguous 3 mm axial images with reformats in the coronal and sagittal planes. No intravenous contrast was administered.
Comparison: NONE
Findings: The paranasal sinuses are well-developed and aerated. There is no mucosal disease or air-fluid level. The cribriform plate appears intact. The nasal septum is fractured on the left, as well as the left nasal bone which is non-displaced. The right zygomatic arch appears intact, however the left zygomatic arch has a fracture line that is non-displaced. The right orbit appears intact. The left orbit shows a comminuted orbital blowout fracture. No osseous lesion or fracture is visualized.
Impression: Left nasal septum fracture, Left nasal bone fracture, nondisplaced, Left zygomatic arch fracture, nondisplaced. Also mentioned, left orbital floor fracture, blowout, comminuted

EXAM: *MRI Thoracic Spine without Intravenous Contrast*
CLINICAL HISTORY: Hemi paralysis
TECHNIQUE: Magnetic resonance images of the thoracic spine without intravenous contrast in multiple planes.
COMPARISON: NONE
FINDINGS: Vertebrae: *Degenerative facet arthropathy lower thoracic spine.* No acute fracture. There is a dislocation of the T3 and T4 vertebraes.
Spinal cord: At T3 level it demonstrates the extent of spinal cord hyperintensity limited to the left hemicord in keeping with the clinical features of Brown-Sequard syndrome.
The vertebral body and disk space heights are preserved.
Impression: Spinal injury- Brown-Sequard syndrome- T3, with T3/T4 dislocation

Diet: Diet as tolerated
Activity: as tolerated per PT evaluation
Wound Care: Daily as needed, Stiches to be removed in approximately 3 days
Follow-up: Follow up with Neurosurgery in 1 week, Oral maxillofacial in 1 week, Orthopedics in 2 weeks
Discharge Plan: Patient was discharged to a rehabilitation center
Time spent for discharge: 60 minutes

Folsom County Fire and EMS
RUN REPORT
Prehospital Patient Care Chart

INCIDENT NUMBER	EMS RESPONSE NUMBER	CALL SIGN	VEHICLE #	INCIDENT DATE
33-4555				11/17/2017

INCIDENT ADDRESS	INCIDENT CITY	INCIDENT STATE	INCIDENT ZIP CODE
Big River Road	Jackson	Ohio	51503

INCIDENT COUNTY
Folsom

INCIDENT LOCATION TYPE:
Street

COMPLAINT REPORTED BY DISPATCH: MVC; rollover

PRIMARY PAYMENT

INCIDENT/PATIENT DISPOSITION
- ☒ **Treated, Transport EMS**
- ☐ No Patient Found
- ☐ Treated, Transferred care
- ☐ Cancelled
- ☐ No Treatment Required
- ☐ Pt Refused Care
- ☐ Treated & Released
- ☐ Dead at Scene
- ☐ Treated, Transported Private Vehicle
- ☐ Treated, Transported Law Enforcement

EMERGENCY MEDICAL DISPATCH PERFORMED
- ☐ No
- ☒ **Yes w/pre-arrival instructions**
- ☐ Yes w/out pre-arrival instructions
- ☐ Yes Unk if pre-arrival instructions given

LEVEL OF CARE - UNIT
- ☐ BLS, EMR
- ☐ BLS, EMT
- ☐ BLS, AEMT
- ☐ ALS, AEMT
- ☒ **ALS, Paramedic**
- ☐ ALS, Nurse
- ☐ ALS, Physician
- ☐ Specialty Critical Care

TYPE OF SERVICE REQUESTED
- ☒ **911 Response**
- ☐ ED to ED Transfer
- ☐ Intercept
- ☐ Mutual Aid

PRIMARY ROLE OF THE UNIT
- ☒ **Transport**
- ☐ Non-transport
- ☐ Supervisor
- ☐ Rescue

LEVEL OF SERVICE
- ☐ BLS, Emergency
- ☒ **ALS, Level 1 Emergency**
- ☐ ALS, Level 2
- ☐ Specialty Care Transport
- ☐ Helicopter
- ☐ Not Applicable

 # OF PATIENTS ON SCENE
- ☐ Single
- ☐ None
- ☒ **Multiple**

MASS CASUALTY
- ☐ Yes
- ☒ **No**

PATIENT LAST NAME	PATIENT FIRST NAME	MI
Krash	Jane	N.

PATIENT ADDRESS ☐ SAME AS INCIDENT	PATIENT CITY	PATIENT STATE	PATIENT ZIP CODE

AGE	DATE OF BIRTH	GENDER	RACE
	4/16/1979	☒ Female ☐ Male	White

CURRENT MEDICATIONS	ALLERGIES	PERTINENT HISTORY
None	UNK	UNK

INJURY PRESENT
- ☒ Yes
- ☐ No

CAUSE OF INJURY MVC, rollover, unrestrained

TYPE OF INJURY
- ☒ Blunt
- ☐ Penetrating
- ☐ Burn
- ☐ Not Known

ALCOHOL/DRUG USE INDICATORS
- ☒ None
- ☐ Pt admits to drug use
- ☐ Smell of alcohol on breath
- ☐ Pt admits to alcohol use
- ☐ Alcohol and/or drug paraphernalia at scene

CHIEF COMPLAINT
Traumatic Arrest s/p MVC

CONDITION CODE

CHIEF COMPLAINT ANATOMIC LOCATION
- ☒ Abdomen
- ☐ Extremity Lower
- ☐ General/Global
- ☒ Chest
- ☐ Back
- ☐ Extremity Upper
- ☒ Head
- ☐ Neck
- ☐ Genitalia

CHIEF COMPLAINT ORGAN SYSTEM
- ☐ CNS/Neuro
- ☐ OB/GYN
- ☐ Pulmonary
- ☐ Global
- ☐ Renal
- ☒ Cardiovascular
- ☐ Psych
- ☐ Skin
- ☐ Musculoskeletal

CARDIAC ARREST
- ☒ Yes, Prior to Arrival
- ☐ Yes, After Arrival
- ☐ No

RESUSCITATION
- ☐ Defibrillation
- ☐ None-DOA
- ☐ Ventilation
- ☐ None-DNR
- ☒ Chest Compressions
- ☐ None-Signs of life

CAUSE OF CARDIAC ARREST
- ☐ Presumed Cardiac
- ☐ Respiratory
- ☐ Unknown
- ☒ Trauma
- ☐ Electrocution
- ☐ Drowning
- ☐ Other

USE OF SAFETY EQUIPMENT
- ☐ N/A
- ☐ Lap Belt
- ☐ Shoulder Belt
- ☐ Protective Clothing
- ☐ Not Known
- ☐ Helmet Worn
- ☐ Protective Non-Clothing Gear
- ☐ Other
- ☐ Child Restraint
- ☐ Eye Protection
- ☐ Personal Floatation Device

AIRBAG DEPLOYMENT
- ☐ None Present
- ☒ Deployed Front
- ☐ Not Deployed
- ☐ Deployed Side
- ☐ Deployed Other

BARRIERS TO EFFECTIVE CARE
- ☐ Development Impaired
- ☐ Physically Impaired
- ☐ Unattended/Unsupervised
- ☐ Hearing Impaired
- ☐ None
- ☐ Physical Restraint
- ☐ Unconscious
- ☐ Language
- ☐ Speech Impaired

RESPONSE MODE	TRANSPORT MODE
☐ ← Lights/Sirens →	☒
☐ ← No Lights/No Sirens →	☐
☐ ← Initial Lights/Sirens Downgraded to no Lights/Sirens →	☐
☐ ← Initial No Lights/Sirens Upgraded to Lights/Sirens →	☐

Initial Call for Help	15:34	Unit Left Scene	15:48
Unit Notified	15:34	Patient arrived at Destination	16:01
Unit En Route	15:35	Transfer of Patient Care	:
Arrive on Scene	15:43	Incident Completed	:
Arrived at Patient	15:44		

PRIOR AID

PERFORMED BY	MEDICATIONS/ PROCEDURES	OUTCOME

INCIDENT NUMBER	UNIT ID	INCIDENT DATE

TRAUMA TRIAGE CRITERIA

- ☐ 2nd/3rd burn >10% BSA or face/feet/hand/genital/airway
- ☐ Amp prox to wrist/ankle
- ☐ Decreasing LOC
- ☐ GCS Motor >4
- ☐ GCS Total ≥13
- ☐ Head/neck/torso crush
- ☐ Extremity inj w/neurovasc comp
- ☐ Extremity crush
- ☐ Torso inj w/pelvic fx
- ☐ Flail chest
- ☐ Torso inj w/abd tender/ distended/seatbelt sign
- ☒ LOC ≥5 min
- ☒ Mech of inj
- ☐ Did not meet any triage criteria
- ☐ Pen inj head/neck/torso
- ☐ Pen inj prox to knee/elbow w/neurovasc comp
- ☐ Spinal cord inj
- ☐ Special Considerations
- ☐ 2+ prox humerus/femur fxs

ADULTS ONLY

- ☐ Pulse >120 w/hemor shock
- ☐ Tension pneumothorax
- ☒ Resp <10 or >29
- ☐ Required intubation
- ☒ SysBP <90, or no radial pulse w/carotid pulse

PEDS ONLY

- ☐ Poor perfusion
- ☐ Resp distress/failure

SYMPTOMS PRIMARY=P ASSOCIATED=A

P	A	
☐	☐	None
☐	☐	Bleeding
☐	☐	Breathing
☐	☐	Changes in Responsiveness
☐	☐	Choking
☐	☐	Death
☐	☐	Device/Equip Prob
☐	☐	Diarrhea
☐	☐	Drainage/Discharge
☐	☐	Fever
☐	☐	Malaise
☐	☐	Mass/Lesion
☐	☐	Mental/Psych
☐	☐	Nausea/Vomiting
☐	☐	Pain
☐	☐	Palpitations
☐	☐	Rash/Itching
☐	☐	Swelling
☐	☐	Transport Only
☐	☐	Weakness
☐	☐	Wound

PROVIDER IMPRESSION PRIMARY=P SECONDARY=S

P	S	
☐	☐	Abd pain
☐	☐	Airway obstruct
☐	☐	Allergic rxn
☐	☐	Altered LOC
☐	☐	Behavior/psych
☒	☐	Cardiac arrest
☐	☐	Cardiac arrhythmia
☐	☐	Chest pain
☐	☐	Diabetic
☐	☐	Electrocution
☐	☐	Hyperthermia
☐	☐	Hypothermia
☐	☐	Hypovolemia/shock
☐	☐	Inhalation/toxic gas
☐	☐	Inhalation/smoke
☐	☐	Death
☐	☐	Poisoning/drug OD
☐	☐	OB/delivery
☐	☐	Resp arrest
☐	☐	Resp distress
☐	☐	Seizure
☐	☐	Sexual assault/rape
☐	☐	Stings/bites
☐	☐	Stroke/CVA
☐	☐	Syncope
☒	☐	Injury
☐	☐	Vag bleed

MEDICATIONS

TIME	MEDICATION	DOSE	ROUTE	REACTIONS See Ref. Sheet
:	NS	Bolus	IO	
:				
:				
:				
:				

PROCEDURES

TIME	PROCEDURE	# ATTEMPTS	SUCCESSFUL	COMPLICATIONS See Ref. Sheet
15:50	IO- rt tibia	1	☒ YES ☐ NO	
15:44	CPR		☐ YES ☐ NO	
:			☐ YES ☐ NO	
:			☐ YES ☐ NO	
:			☐ YES ☐ NO	

VITAL SIGNS See Ref. Sheet

TIME	PULSE	SYS BP	DIA BP	RESP	O2 SAT	GCS EYE	GCS VERBAL	GCS MOTOR
15:51	0	0	0	0	90	1	1	1
:								
:								
:								
:								

ADV DIRECTIVE

- ☐ State DNR Form
- ☐ Other Healthcare DNR
- ☐ Family Request DNR (no form)
- ☒ None
- ☐ Living Will
- ☐ Other

DESTINATION

Man in Black Medical Center

TYPE OF DESTINATION

- ☒ Hosp ED/OR/L&D
- ☐ Other EMS (air)
- ☐ Other EMS (ground)
- ☐ Other

REASON FOR CHOOSING DESTINATION

- ☒ Closest
- ☐ Diversion
- ☐ Family Choice
- ☐ Insurance
- ☐ Law Enforcement Choice
- ☐ On-line Med Control
- ☐ Other
- ☐ Pt. Choice
- ☐ Pt. Physician's Choice
- ☐ Protocol
- ☐ Specialty Resource Center

ED DISPOSITION

- ☐ Admit-floor
- ☐ Admit-ICU
- ☒ Death
- ☐ Discharge
- ☐ Transfer-other hosp

HOSPITAL DISPOSITION

- ☐ Death
- ☐ Discharge
- ☐ Transfer-other hosp
- ☐ Transfer-nursing home
- ☐ Transfer-other
- ☐ Transfer-rehab

NARRATIVE:

Front passenger of van went off road down a ditch. Upon EMS arrival patient in traumatic arrest. Patient was extricated and loaded into Ambulance. CPR was in progress. An IO was placed in the right tibia and fluids began.

CREW MEMBER	CREW MEMBER	CREW MEMBER
CREW MEMBER	CREW MEMBER	CREW MEMBER

Man in Black Medical Center

Patient Sticker:
Jane Krash
4/16/1979
MR# 934158

Date: 11/17/2017 Patient Arrival Time: 16:01

‰ N/A Pre-Hospital Treatment		
Transporting Ambulance		
O2 @ _L/min/	IV: Needle size_	**Backboard**
NC NRB Ambu	IO NS	**Long** Short Ked
Airway	Medications	Scoop
Oral Nasal Other	_____	Bilateral Head Supports
ET tube # _____ @ cm	C-Collar on: **Yes** **X** ___ No	Splint on
	_____	Ice on
CPR started @ 1544	_____	Dressing
		Other

Date of Injury: 11/17/17 Time of Injury: ND Pre-hospital trauma team alert notification: **Yes** No

Hospital Trauma Team Activation Yes X No____ Time of Trauma Team Activation: 15:55

Trauma Team Members		
Team members notified:	Time Called	Time Arrived
‰ Nurses x	15:55	15:56
‰ Physician / CNP / PA	15:55	15:59
‰ Lab	15:55	15:58
‰ X-ray	15:55	15:59
‰ Other		

Type of Vehicle	
Car	Pedestrian
Truck	ATV
Motorcycle	Boat
Bicycle	
Other _____	

Mechanism of Injury	
Speed of vehicle _____65 MPH	**Rollover**
Number of vehicles	Ejected
1 2 3 >3	Rearend
Steering wheel deformity	T-Bone
Starred windshield	Head on

Restraint Devices	
Lap belt	**Airbag deployed**
Shoulder belt	Helmet
Car seat	Unrestrained

Fall	Penetrating	Blunt	Thermal	Other
Fell from: _____	GSW _____	Assault _____	Burn _____	Hanging _____
	Stabbing _____	Crush _____	Heat exposure	Near drowning
Height_____ ft.	Other _____	Other _____		
			Cold exposure	Animal related

Initial Assessment

AIRWAY

Patent	Suctioning
Oral Airway	**Bag Mask**
Nasal Airway	O2 _____ L.
ET **7.0**	Comments
Trach	
Crico	

BREATHING

Spontaneous			Respiratory Effort	
R	L		Normal	Agonal
		Lung sounds	Shallow	Nasal flaring
		Clear	Stridor	Tachypnea
		Rales	Dyspnea	Grunting
		Rhonchi/Wheezes	Retracting	**Absent**
		Decreased	Intercostal	Paradoxical
X	X	Absent	Substernal	Cough

Smoker Yes **No** Unk

CIRCULATION

Capillary Refill:	**None**	Delayed (> 2 sec)	Normal (< 2 sec)	
Pulses Present:	Carotid	Femoral	Radial	Pedal
Palpated Pulse	Regular		Irregular	
Heart tones	Audible		**Absent**	
Jugular Vein Distension	**No**	Yes		
Bleeding	Controlled	Uncontrolled	**NA**	
Skin Color	Pink		Dusky	
	Pallor		Cyanotic	
	Flushed		Mottled	

DISABILITY

Glasgow Coma Score		Initial	Disch
Eye Opening			
Spontaneously	4	1	1
To Speech (Shout)	3		
To Pain	2		
No Response	1		
Verbal Response			
Oriented (Coos, Babbles)	5		
Confused (Consolable, Cry)	4		1
Inappropriate Words (Persistent Cries, Screams)	3	1	
Incomprehensible Words (Grunts, Restless)	2		
No Responses	1		
Motor			
Obeys (Spontaneous)	6		
Localized Pain	5	1	
Withdrawal to Pain	4		1
Flexion to Pain (Decorticate)	3		
Extension to Pain	2		
No Response to Pain	1		
Total GCS Score		3	3

Allergies: UNK

Tetanus: _ LMP: UNK Wt: UNK

Procedures

Time	Procedure	Results
16:03	ET Tube X Combitube ____	Size 7.0 Secured @ 22 cm FiO2 %
16:05	Central Line/ IV	Size 18 Fr Site R neck Solution_NS
	Warming Measures	**Fluids** Mechanical Bair Hugger Blankets
	NG Tube	Size _____ Color _____
	Foley / Quick Cath	Size _____ Color _____
	Neck immobilization C-Collar Applied: in place on arrival	CMS: Before _____ After _____
	Splinting _____	Location: _____

Area of Injury

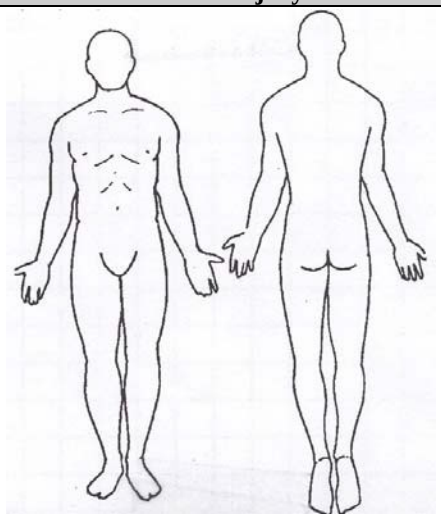

A = Abrasion	Fc = Closed Fracture	OW = Open Wound
B = Burns	Fd = Dislocation	P = Paralysis
C = Crepitus	Fo = Open Fracture	S = Edema
D = Deformity	L = Laceration	Ta = Total Amputation
E = Ecchymosis		Na = Near Amputation

Secondary Assessment

Head/Scalp		Eyes	Mouth	Ears
Intact	Rash	PEARL	**Intact**	**No drainage**
Laceration	Burns	Raccoon eyes	Teeth	Drainage
Abrasions	Pain	EOMS follows	Missing teeth	Right / Left
Bruising	Battle Signs	Visual Acuity OD ____/_ ___	Dentures intact	Clear / Clear
		OS ____/____	Comments_____	Blood / Clear

Neck		Chest		Heart Sounds
Intact	**C-Collar**	Symmetrical	Chest Pain	Present
Swelling	Pain	Asymmetrical	Location _____	Distant
Trachea midline		Paradoxical movement	Time of onset _____	**Absent**
Trachea deviated		Location _____	Activity @ onset _____	
Sub-q emphysema		**Crepitus**	Flail chest	
Difficulty swallowing		Location_____	Other _____	

Abdomen / Pelvis / GU

Abdomen			Bowel Sounds	Pelvis
Soft	**Distended**	Last Intake:	Present	Intact
Nontender	Rigid	Food _____	**Absent**	Pain _____
Tender		Liquid _____	Hyperactive	Blood at meatus _____
Comments: _____			Hypoactive	Blood at rectum _____
				Instability _____

Posterior	Extremities
Intact	**Intact**
Deformity	Fracture
Pain	Pain
Comments _____	Deformity
	Comments _____

Time	Temp	P	R	BP	SaO2	O2 L/min	Pupil Reaction (S-slow, U-unequal, B-brisk, D-dilated, F-fixed, = - Equal, C-closed by swelling)		Pain Scale 0-10 Pain		Comments
									Scale	Type	
1602		0	0	0/P	90	assisted	**Right**	**Left**			PULSE CHECK
1605		0	0	0/P	90	assisted	FD	FD			PULSE CHECK
1608		0	0	0/P	90	assisted	FD	FD			PULSE CHECK
1612		0	0	0/P	90	assisted	FD	FD			PULSE CHECK
1615		0	0	0/P	90	assisted	FD	FD			PULSE CHECK
1620		0	0	0/P	90	assisted	FD	FD			PULSE CHECK
1624		0	0	0/P	90	assisted	FD	FD			PULSE CHECK
1628		0	0	0/P	90	assisted	FD	FD			PULSE CHECK
1632		0	0	0/P	90	assisted	FD	FD			PULSE CHECK
1632	Pronounced dead										

Medications Given

Medication	Dose	Route	Time Given	Initials
Epi	1mg	IV	1602	RKH
Epi	1mg	IV	1608	RKH
Epi	1mg	IV	1612	RKH
Epi	1mg	IV	1620	RKH
Epi	1mg	IV	1624	RKH
Epi	1mg	IV	1628	RKH
Epi	1mg	Iv	1631	RKH

Input				**Output**			
Source	**Prior to Arrival**	**ED**	**Total**	**Source**	**Prior to Arrival**	**ED**	**Total**
IV Fluids	.5L	3.5L	4L	Urine			
				Emesis			
				Chest Tube		600mL	
				Other			
Blood							
Fresh Frozen Plasma							

Personal Belongings

Clothes
Purse
Wallet
Jewelry
Given to: _____
Name
Relationship _____
Nursing Staff _____
_____

Nurse Notes: Patient arrived at 1601 in arrest following a rollover MVC. Front seat passenger, airbag deployed, no seatbelt. Patient has multiple contusions. ED MD noted patient has instability in LLE. CPR in progress and an IO was placed in right tibia by EMS prior to arrival. Patient is in PEA. Dr. Seeger placed an EJ in right neck and intubated the patient with a 7.0 ETT. 7mg of epi were given. Dr. Benny placed chest tube on the left side and performed a thoracotomy. Time of death was 1632. County coroner picked the patient up from the ED at 1739.

RN Signature: RKH

Physician Checklist LifeCenter Referral/Death Notification replaces "lifeCenter

Patient Name Jane Krash MRN 934158

Date & Time of Death 16:32 11/17/1017 DOA: D Yes **D No**

Death Pronounced by Dr. Jack Benny

Parent/Guardian: **Notified Present** Name/ Relationship: Suzanne Morris; Mother

Reportable to Coroner? (see reference list in death packet): **D Yes** D No
If yes, does the Coroner take jurisdiction: **D Yes** D No

If not reportable to Coroner or Coroner does not take jurisdiction:
Autopsy Requested by· Granted: D Yes D No
Autopsy: D Yes D No

Notify LifeCenter Referral Hotline, ***within 1 hour*** of death. *Must refer regardless of any earlier notification prior to death
Notified by: Rachel Huntington, RN

Date Called 11/17/2017 Time 16:41 Reference Number (Required) 653781

D Referral Hotline determines patient is Medically Suitable for Tissue/Eye Donation. List tissues suitable for
request_____

D Patient determined Medically Unsuitable for tissue and/or eye donation by the Referral Hotline

Dr. Maybell Seeger from Man in Black Medical Center called to report the death of Jane N. Krash WF38. It was reported the decedent was involved in a one car accident at approximately 15:30 on 11/17/2017 where she was a front seat passenger. The minivan swerved to avoid a deer in the roadway and subsequently went off the roadway rolling over multiple times ultimately colliding with a tree. The decedent was reported to not have been restrained in her seat belt. The decedent was taken to MBMC by medics where she was admitted at 16:01 hours and she was pronounced dead at 16:32 hours by Dr. Benny. The decedent had abdominal injuries including trauma to her liver. No additional medical history was reported. The accident is being investigated by the Folsom County Sheriff's Department. The remains were brought to the FCCO for examination. Admitting blood was requested and medical records were placed in the Epic mailbox.

Luther Perkins,
Investigator

POSTMORTEM EXAMINATION
OF THE BODY OF

Jane N. Krash
Case # - 22-3477
Folsom County

I. Blunt force torso trauma due to motor vehicle crash:

   A. Laceration, liver (extensive destruction of left and right lobes).

   B. Status post left thoracotomy with evidence of surgical dissection near thoracic aorta consistent with cross clamping attempt.

   C. Partial-thickness laceration, IVC near atrium attachment.

   D. Bilateral hemothoraces.

II. Ethanol and cocaine intoxication.

III. Arteriosclerotic cardiovascular disease.

IV. Cholelithiasis.

OPINION

It is my opinion that the cause of death of Jane N. Krash is:
Blunt force torso trauma.

It is my opinion that the manner of death is: Accident.

_____ _____

Marshall Grant, M.D., Forensic Pathologist Date
Coroner, Folsom County, Ohio

A postmortem examination of the body of a 38-year-old white female, identified as Jane N. Krash, is performed at the Folsom County Coroner's Office on November 18, 2017. The examination is conducted by Marshall Grant, M.D., J.D., M.B.A., and is begun at 8:25 a.m.

CLOTHING:

The body is received clad in a shirt, which has been cut presumably during resuscitative attempts.

PROPERTY:

Accompanying valuables include two hair ties.

IDENTIFICATION TAGS:

A Montgomery County Coroner's Office identification tag is around the right ankle with a hospital identification band around the left wrist and a toe tag around the right great toe.

EXTERNAL EXAMINATION:

The body is that of a well-developed, well-nourished, adult female; 138 pounds and 66 inches, whose appearance is appropriate for the reported age. The body is cold following refrigeration. Rigor mortis is generalized. Livor mortis is red-purple, posterior, and blanches with pressure.

Scalp hair is dark brown with a normal distribution. Irides appear green. Sclerae and conjunctivae are clear, free of petechiae. The nose and ears are not unusual. Teeth are natural and the tongue appears normal.

The neck is unremarkable. The thorax is well developed with evidence of surgical intervention of the chest as well as abdomen. The anus and back are unremarkable. External genitalia are those of a well-developed adult female. Breasts are symmetrical and without palpable masses.

Upper and lower extremities are also well developed and symmetrical without significant injury.

IDENTIFYING MARKS:

Identifying marks include multiple tattoos on the abdomen, wrists, and back.

EVIDENCE OF MEDICAL INTERVENTION:

An endotracheal tube is appropriately positioned and inserted through the mouth. An oxygen saturation monitoring device is adhered to the left middle finger with an intravenous catheter inserted in the right forearm. There is an intraosseous catheter in the right tibia and an additional oxygen saturation monitoring device adhered to the left ear lobe. There is also a left thoracotomy with sutured incisions in these locations.

Internal examination reveals apparent surgical dissection around the lower thoracic aorta, suggestive of a site for cross-clamping.

EVIDENCE OF INJURY:

The right frontotemporal scalp has a 3 x 2 inch abrasion. The right lateral hip has a series of four 1 x 1/2 inch contusions, while the left middle finger has a 1/2 x 1/2 inch contusion. The right forearm has a pair of 1/2 x 1/2 inch contusions.

Despite minimal external injuries, internal examination reveals massive laceration involving the right and left lobes of the liver with approximately 50% of its parenchyma disrupted. There is 500 mL of blood in the left chest and 300 mL of blood in the right chest. Additionally, there is a partial-thickness rent of the endocardium of the inferior vena cava near its attachment to the right atrium. This injury is without accompanying hemopericardium.

INTERNAL EXAMINATION:

Lungs are atelectatic. The mediastinum is in the midline. The diaphragm is without abnormality. The abdominal cavity has minimal residual blood and the chest cavities have the previously-described bilateral hemothoraces.

CARDIOVASCULAR SYSTEM:

The heart is 280 grams. Epicardial surfaces are smooth, glistening, and unremarkable. The pericardial sac is free of significant fluid or adhesions. Coronary arteries arise normally, following a right-dominant pattern with 75% atherosclerotic narrowing of the left anterior descending coronary artery and 50% narrowing of the left circumflex vessel. The right main coronary artery is narrowed by 40% with atherosclerotic plaque. Cardiac chambers and valves have the usual size and position relationship. The right ventricular wall thickness is 0.4 cm; the free left ventricular wall and interventricular septum both measure 1.4 cm in thickness. The myocardium is uniform red-brown, free of abnormal markings with exception of the partial-thickness laceration of the inferior vena cava its right atrial attachment. Atrial and ventricular septa remain intact. The aorta and its major branches arise normally and follow the usual course with fatty streak atherosclerosis. The vena cava and its major tributaries are thin walled and patent, in the usual distribution.

RESPIRATORY SYSTEM:

Right and left lungs weigh 335 grams and 295 grams, respectively. The tracheobronchial tree is patent and mucosal surfaces intact. Pleural surfaces are translucent, smooth, and glistening. Pulmonary parenchyma is

atelectatic with minimal edema fluid or blood exuding from cut surfaces. Pulmonary arteries and veins are normally developed and patent.

DIGESTIVE/HEPATOBILIARY SYSTEM:

The esophagus is lined by intact tan smooth mucosa. The gastric mucosa is flattened by autolysis and the lumen contains 10 mL of brown liquid. Small and large intestines are unremarkable. The mesentery and omentum appear normal. The colon contains formed stool. The pancreas has the usual tan lobulated parenchyma, and the ducts are clear.

The 1185-gram liver has a markedly disrupted capsule and underlying brown parenchyma secondary to trauma. The thin-walled gallbladder contains multiple gallstones as well as 20 mL of viscid bile; extrahepatic biliary tree is patent.

ENDOCRINE SYSTEM:

Pituitary, thyroid, and adrenal glands are unremarkable.

GENITOURINARY SYSTEM:

Normal-shaped kidneys are symmetrical and together are 235 grams. Capsules are smooth, thin, semitransparent, and strip with ease from the underlying smooth, red-brown cortical surfaces. Cortices are sharply delineated from the medullary pyramids. Calyces, pelves, and ureters are unremarkable. The urinary bladder contains no urine, with 300 mL of urine in the Foley catheter collection device. The urinary bladder mucosa is gray-tan and intact.

The vaginal cuff is unremarkable. The uterus and ovaries are those of a reproductive-age female without evidence of a current gestation. The right ovary does have a benign-appearing smooth-walled cyst.

HEMATOPOIETIC SYSTEM:

The thymus is dispersed in anterior mediastinal fat. The 90-gram spleen has a smooth intact capsule covering red-purple parenchyma. Regional lymph nodes have the usual distribution and appearance. Bone marrow is red-brown and homogeneous, without focal abnormality.

MUSCULOSKELETAL SYSTEM:

The bony framework, supporting musculature, and soft tissues are not unusual.

NECK:

Examination of the soft tissues of the neck, including strap muscles and large vessels, reveals no abnormalities. The hyoid bone and larynx are intact. The tongue is serially sectioned and unremarkable.

NERVOUS SYSTEM:

The brain weighs 1340 grams. Dura mater and falx cerebri are intact, and leptomeninges thin and delicate. Cerebral hemispheres are symmetrical, with a normal pattern and distribution of sulci and gyri. Structures at the base of the brain, including cranial nerves and blood vessels, are intact and free of abnormality. Sections of the cerebral hemispheres reveal no lesions within the cortex, subcortical white matter, or deep parenchyma of either hemisphere. Cerebral ventricles are of normal caliber, containing clear cerebrospinal fluid. Sections through the brainstem and cerebellum are unremarkable.

SPECIAL STUDIES:

Routine toxicology studies reveal ethanol and marijuana intoxication.

MICROSCOPIC EXAMINATION

HEART: Myocardium is unremarkable as is the sinoatrial (SA) node. Attempted sections of the atrioventricular (AV) node contain no conduction tissue; however, there is abundant extravasated blood in the right atrium, consistent with gross partial-thickness laceration at the IVC within this area.

LUNGS: Anthracosis and diffuse alveolar collapse (consistent with gross atelectasis).

LIVER: Intraparenchymal fragmentation consistent with gross laceration. There is also mild steatosis.

ADRENAL GLAND, KIDNEY, PITUITARY GLAND, SPLEEN, BRAIN, AND PANCREAS: No significant histopathologic abnormality in sections examined.

MEG:sm
11/19/2017

Man in Black Medical Center
1929 Hurt Way
Jackson, OH 51503

CHEMISTRY REPORT

Patient: Krash, Jane N. **MRN : 934158**
DOB: 4/16/1979 **ENCOUNTER NO: 49761304**

Date: 11/17/2017
Time: 16:15

Toxicology Urine Results Group:

	Result
Amphetamine	Negative
Barbiturates	Negative
Benzodiazepine	Negative
Buprenorphrine	Negative
Cannabinoid	Negative
Cocaine	Positive
Methadone	Negative
Methamphetamine	Negative
Oxycodone	Negative
Prooxyphene	Negative
Opiates	Negative
Tricyclic Antidepressent	Negative